

# Hugs and Kisses

Frank, post orthopedic surgery was non weight-bearing and not recovering well. Clearly in pain, and not eating.

4 doctorVet treatments in 6 days, and...

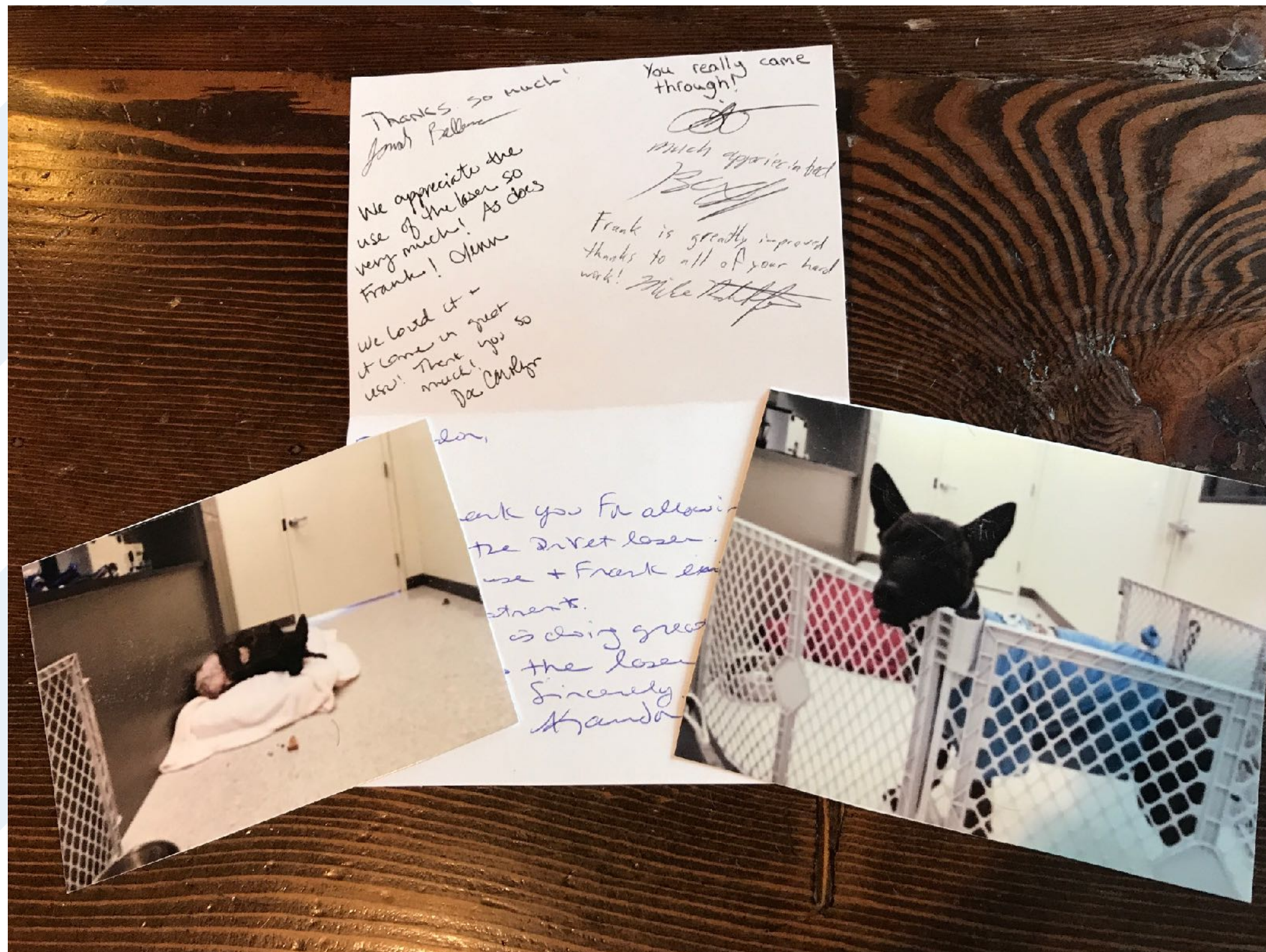



# Hugs and Kisses

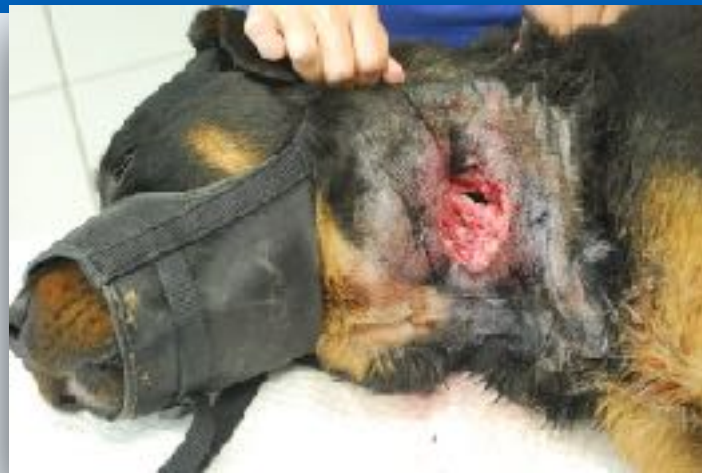Frank, post orthopedic surgery was non, weight-bearing and not recovering well. Clearly in pain, and not eating.

4 doctorVet treatments in 6 days, and...

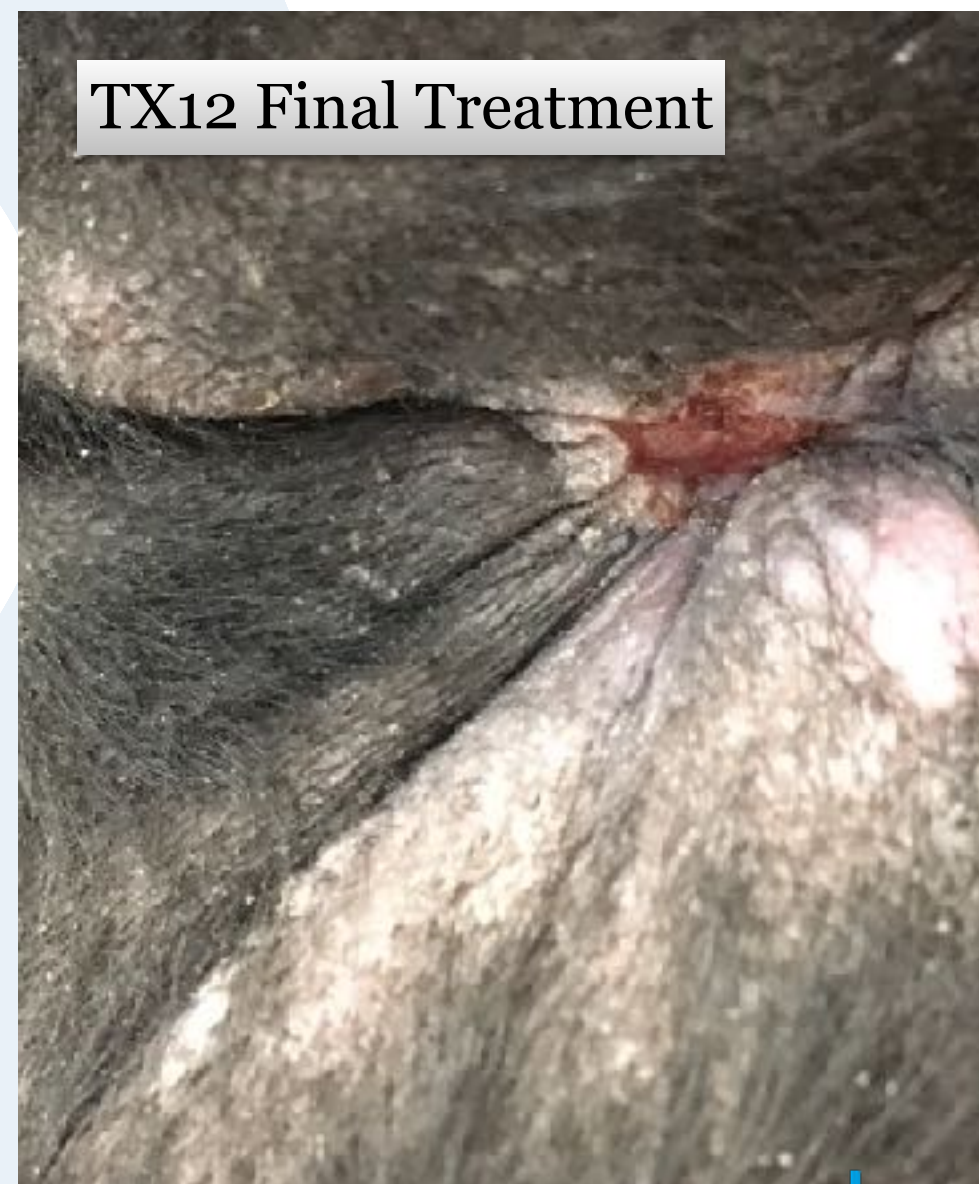
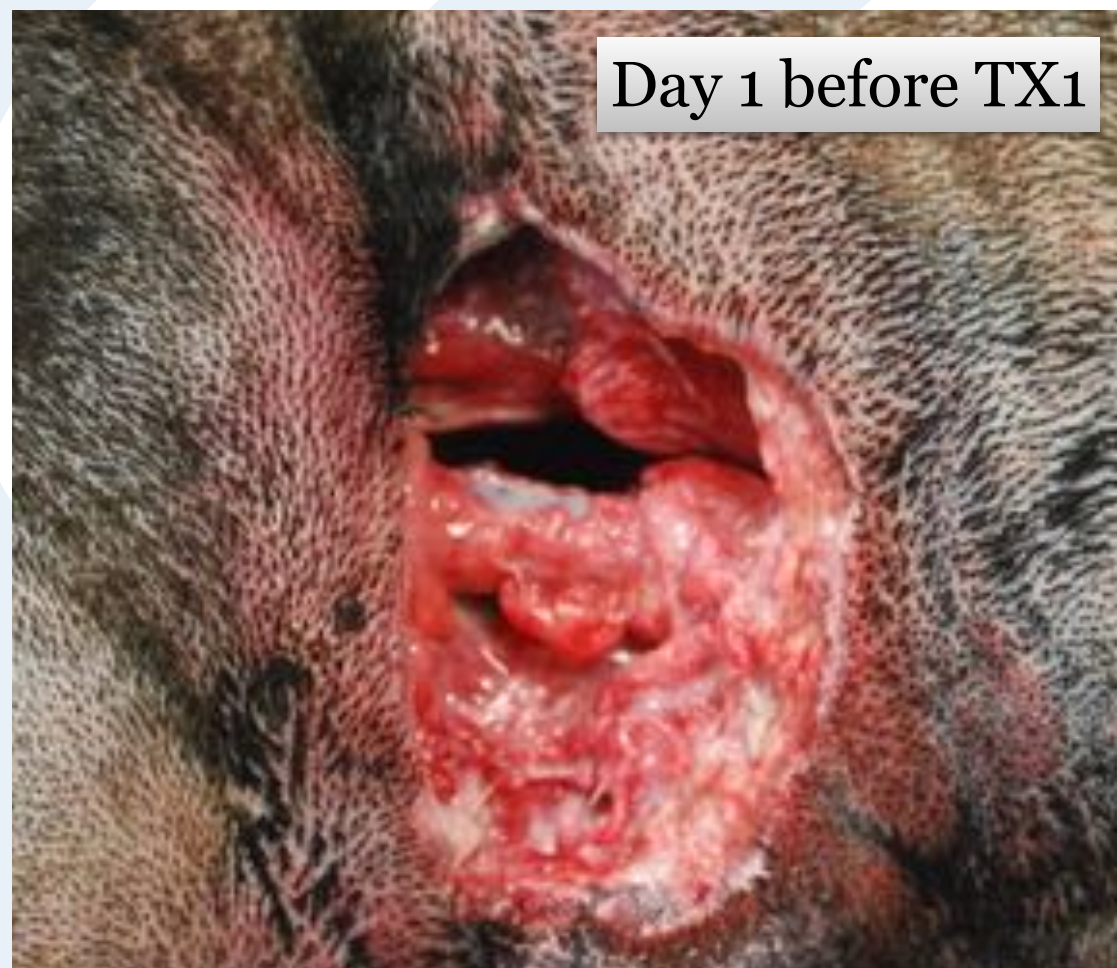


# Wound Healing - Bentley (5cm wound)



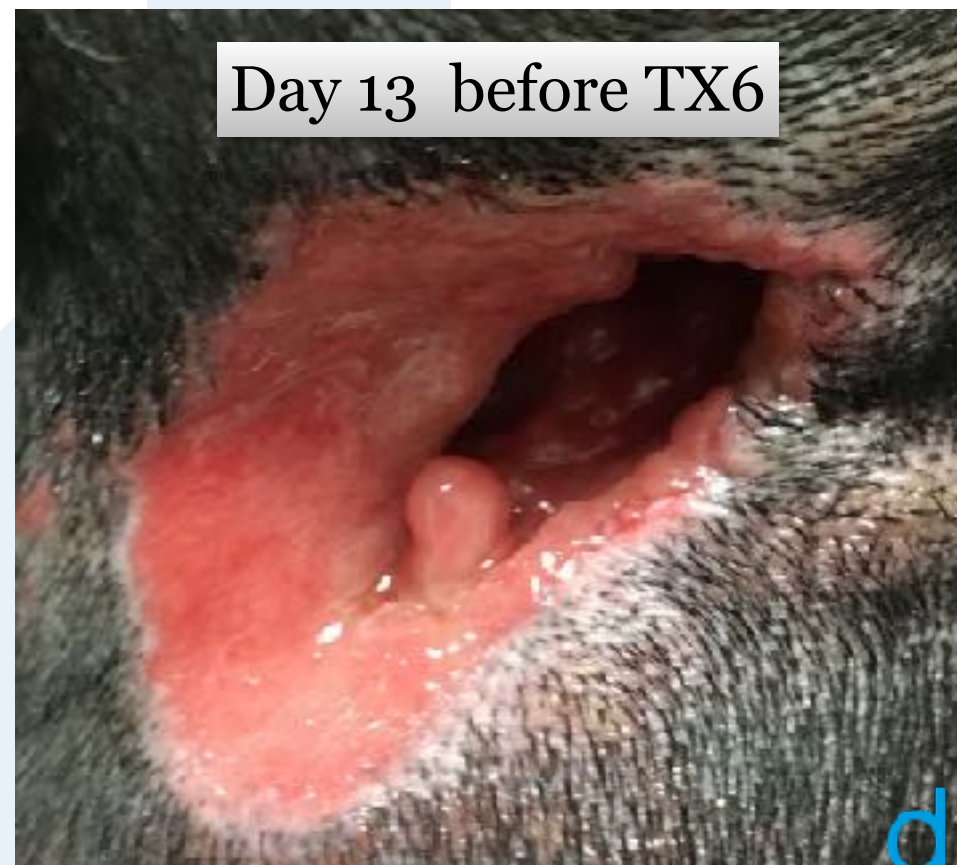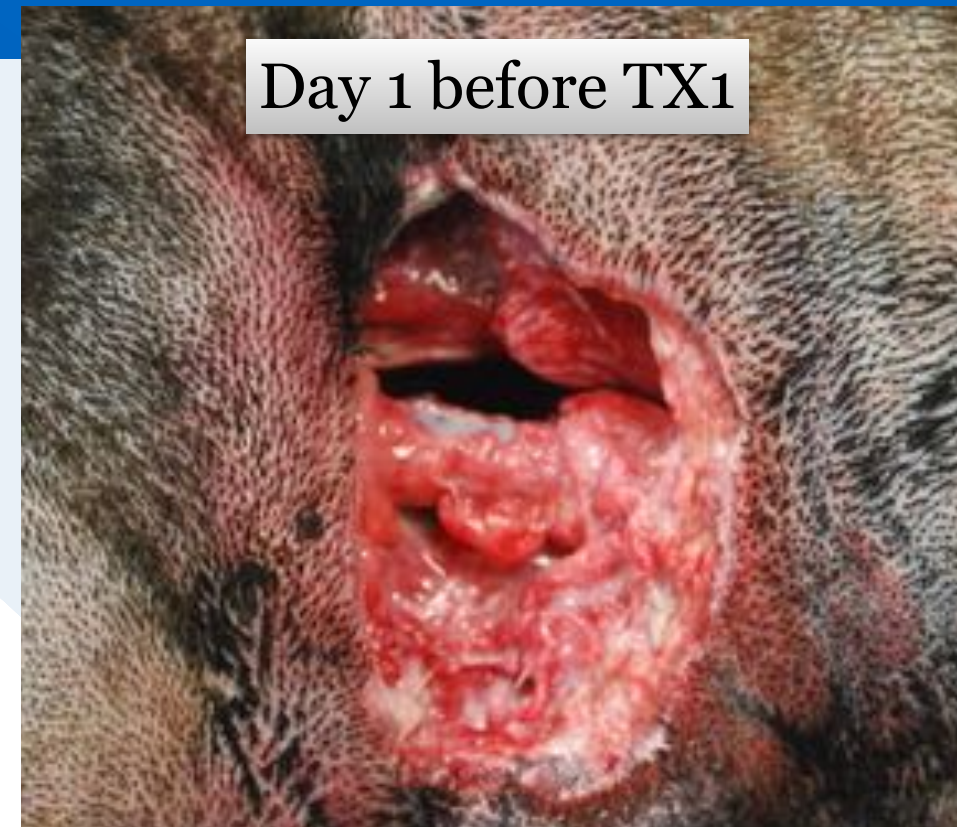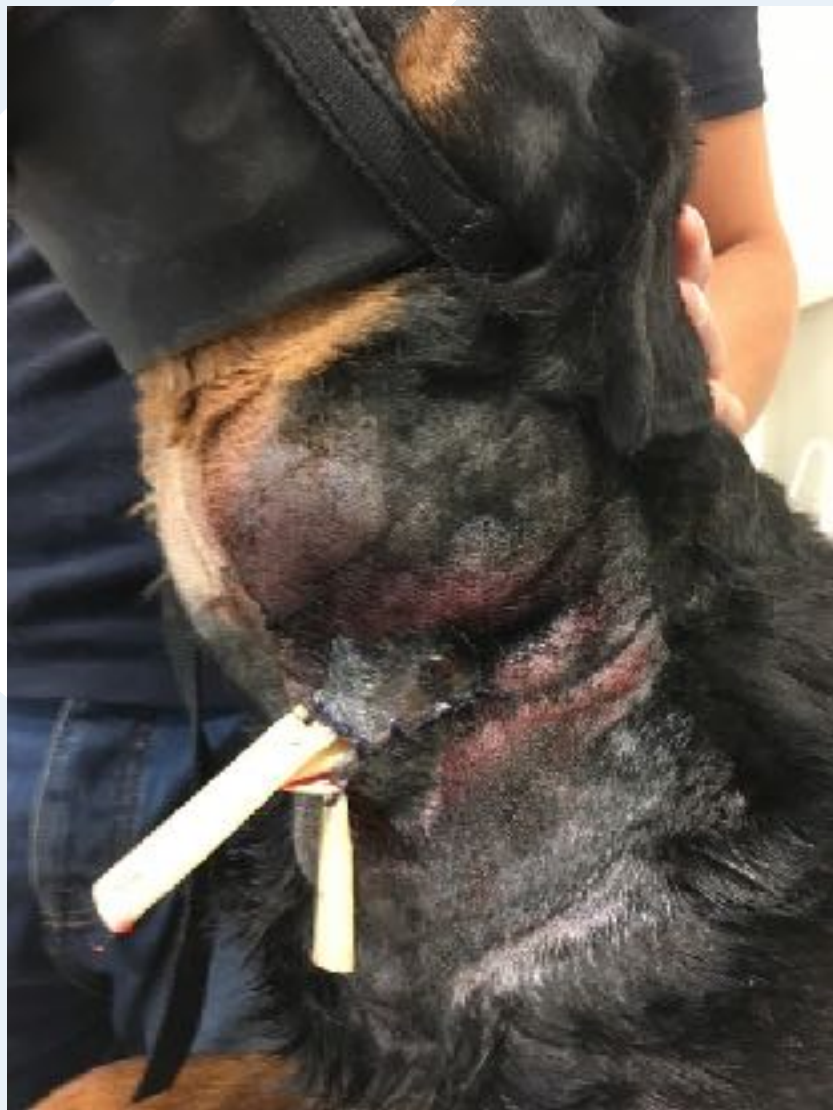Huge neck abscess. Surgical opening and drain placed, but skin became necrotic. Wound opened. Removed necrotic skin and used doctorVet laser for second intention healing.





# Wound Healing - Bentley (5cm wound)

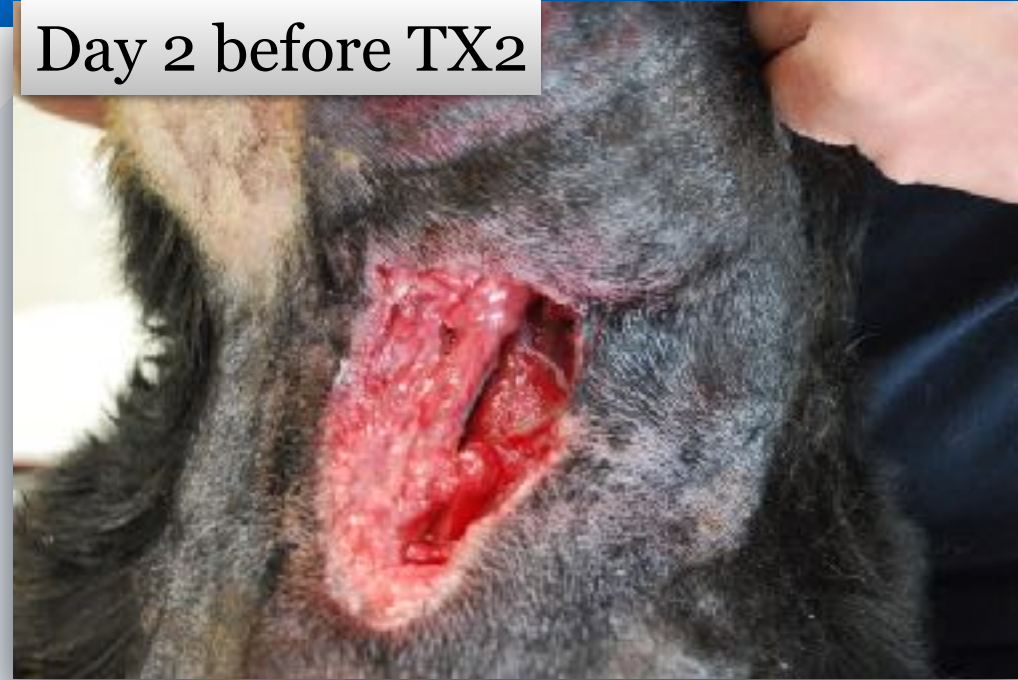Huge neck abscess. Surgical opening and drain placed, but skin became necrotic. Wound opened. Removed necrotic skin and used doctorVet laser for second intention healing.



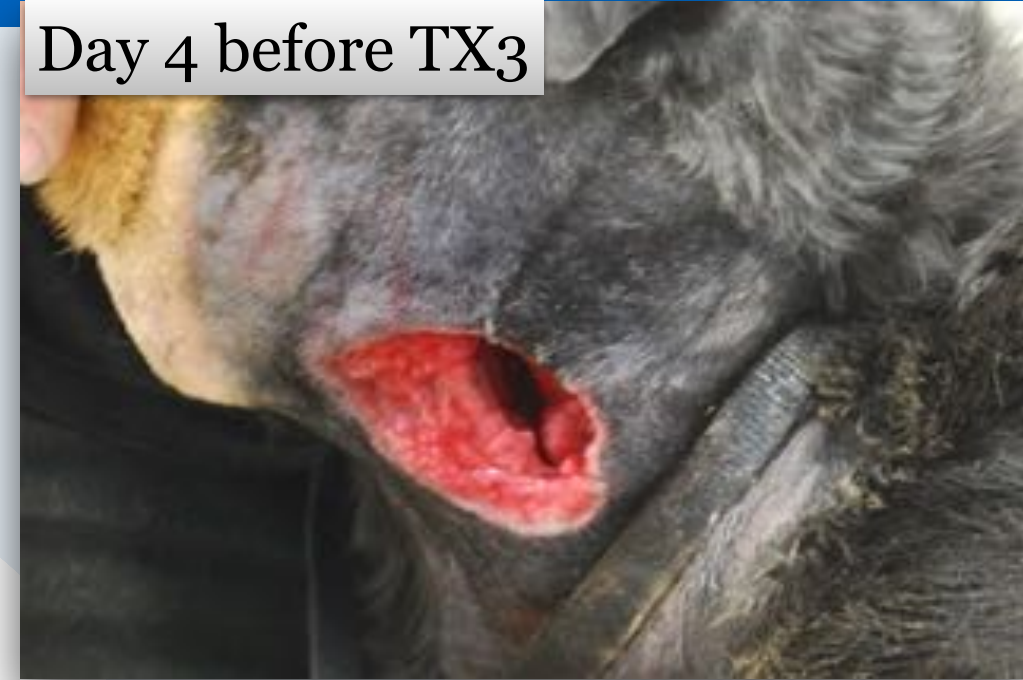

# Wound Healing - Bentley (5cm wound)

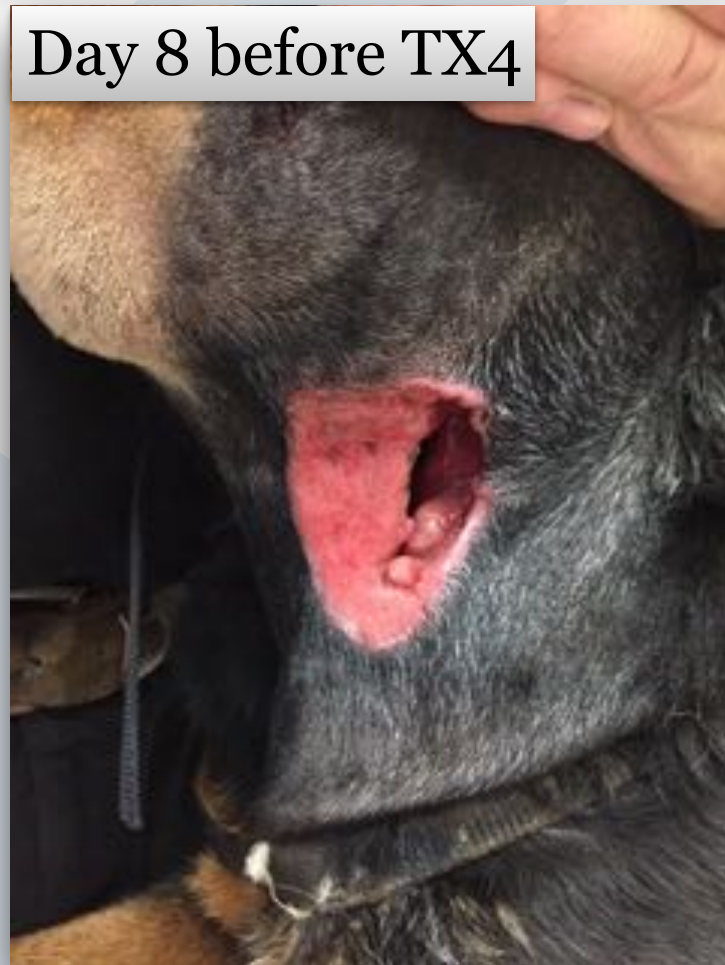Day 2 before TX2



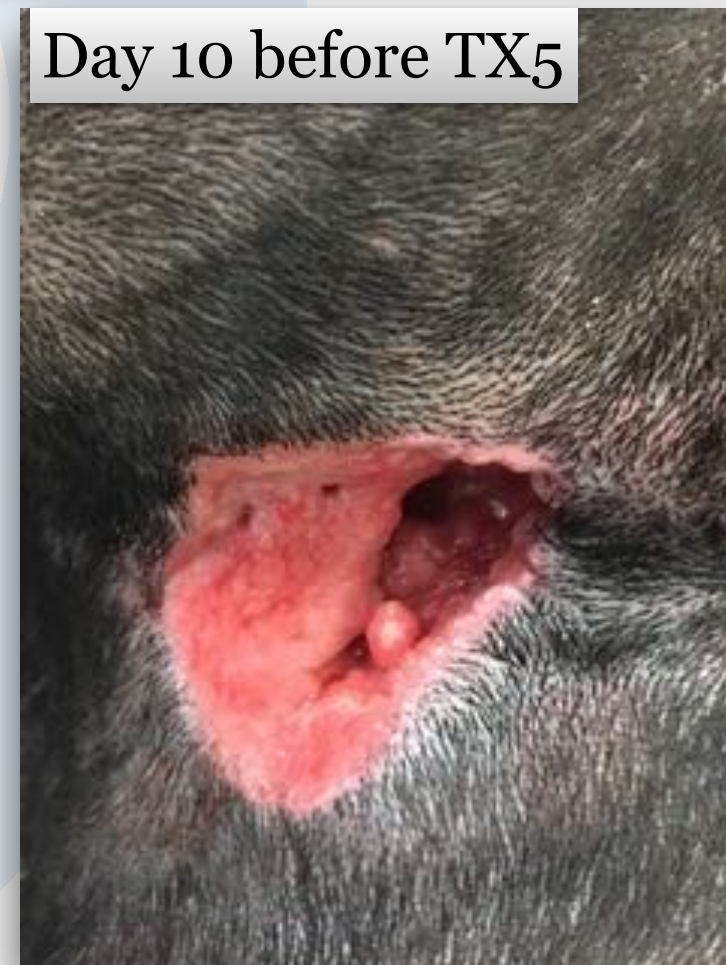Day 4 before TX3



Day 8 before TX4



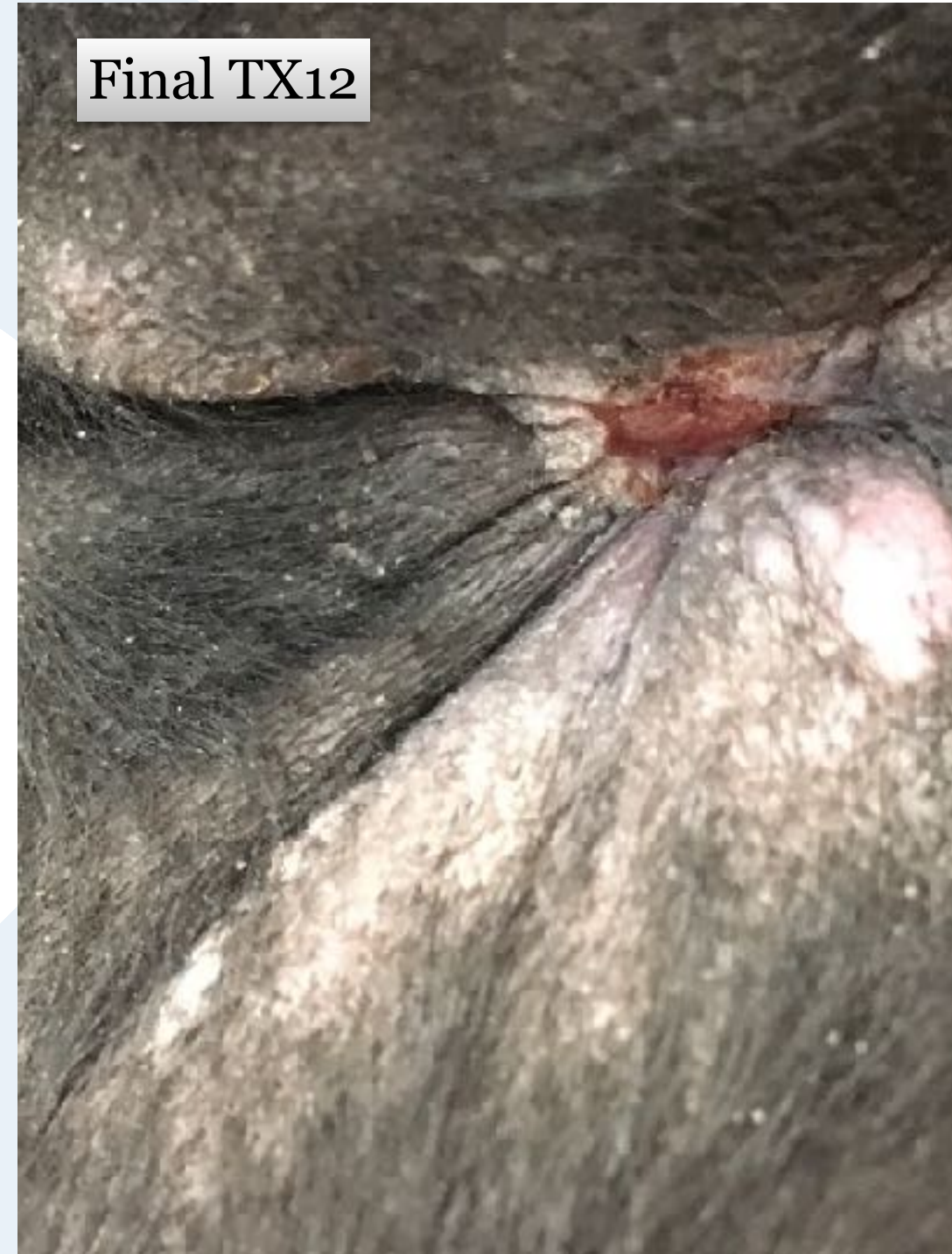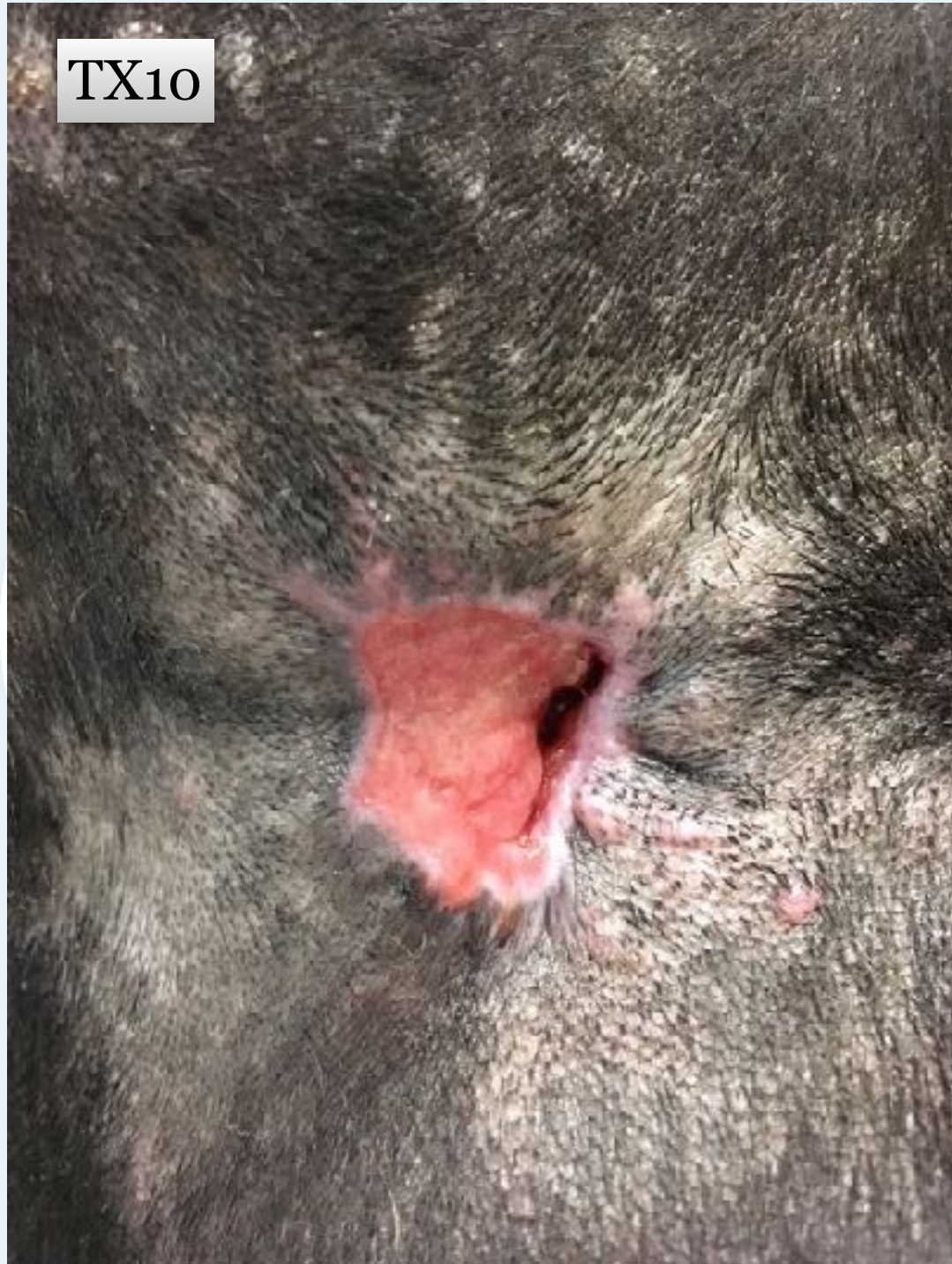Day 10 before TX5



*Case Courtesy of Dr. Wendy Haelterman*



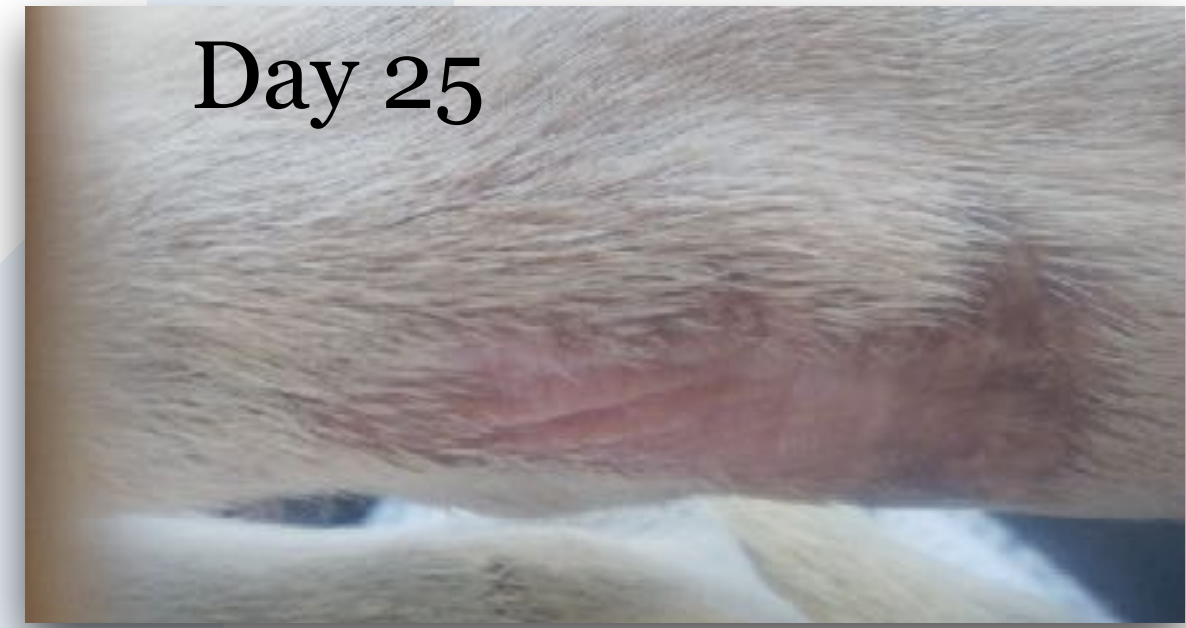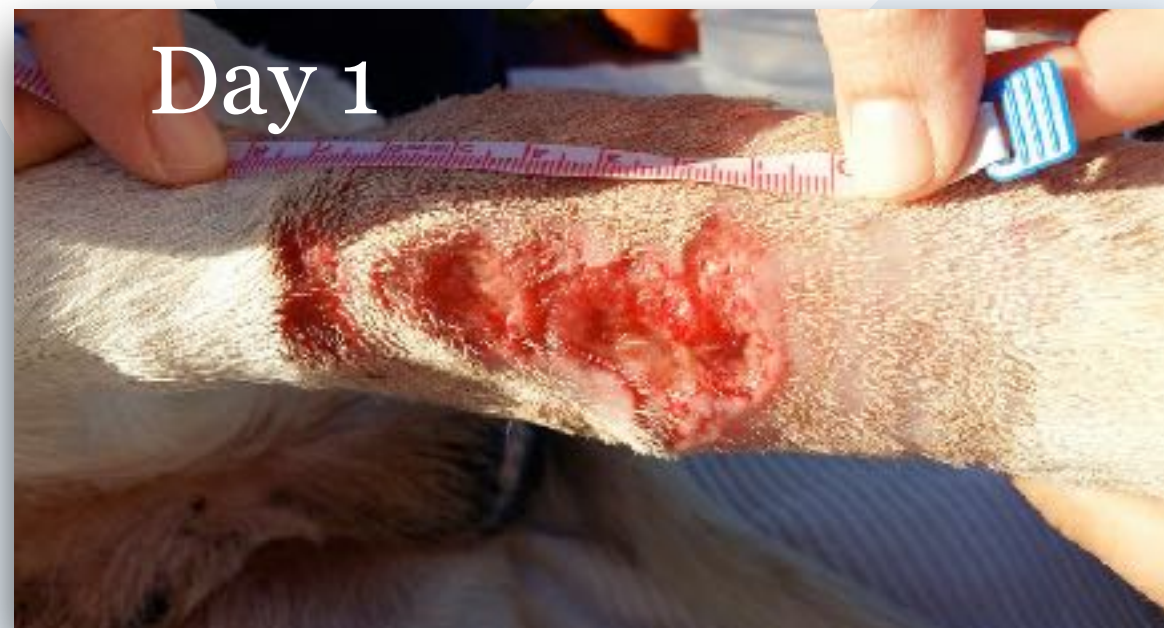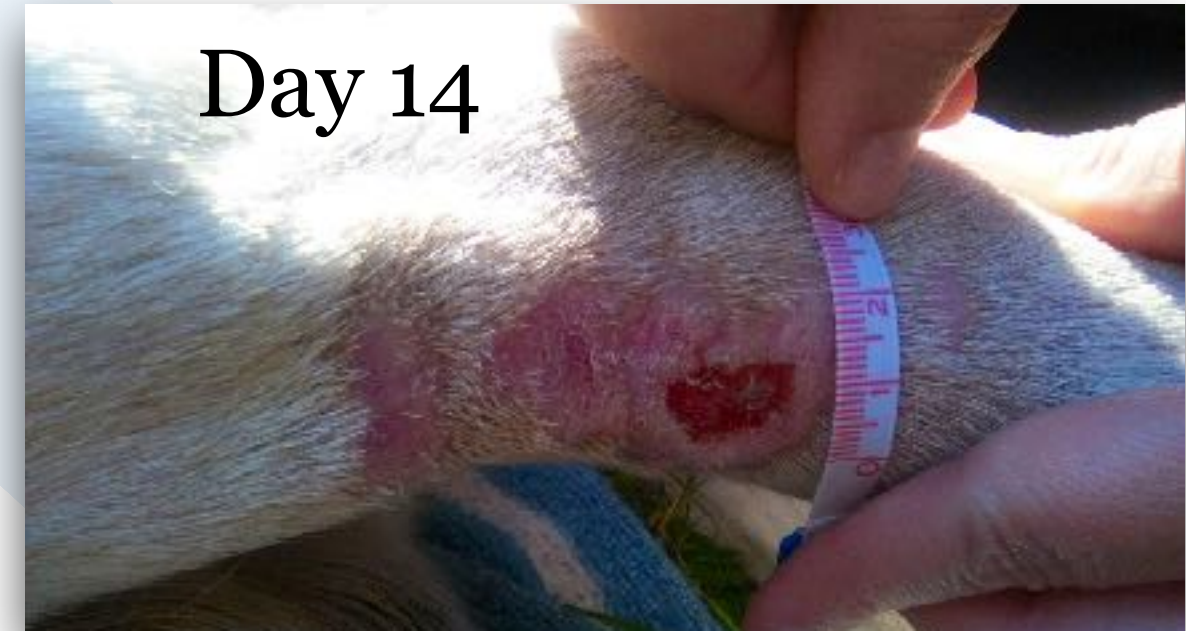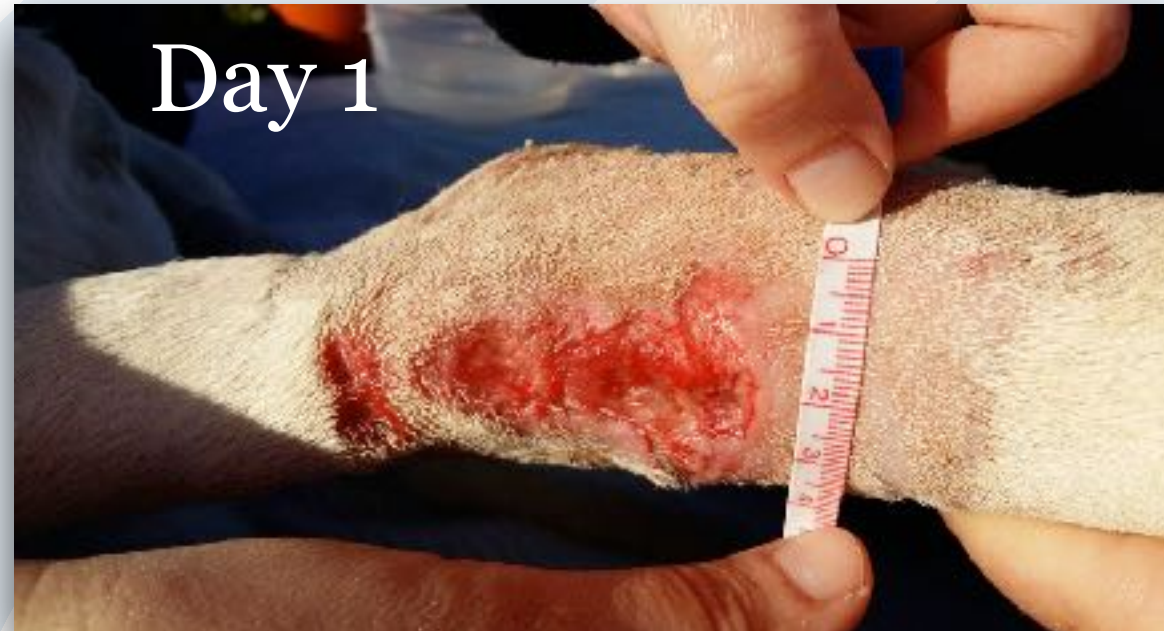# Wound Healing - Bentley (5cm wound)



*Case Courtesy of Dr. Wendy Haelterman*



# Wound Healing - Ziggy



*Case Courtesy of Dr. Fina Cardona Marí, BSc, MSc- (case history on back)*



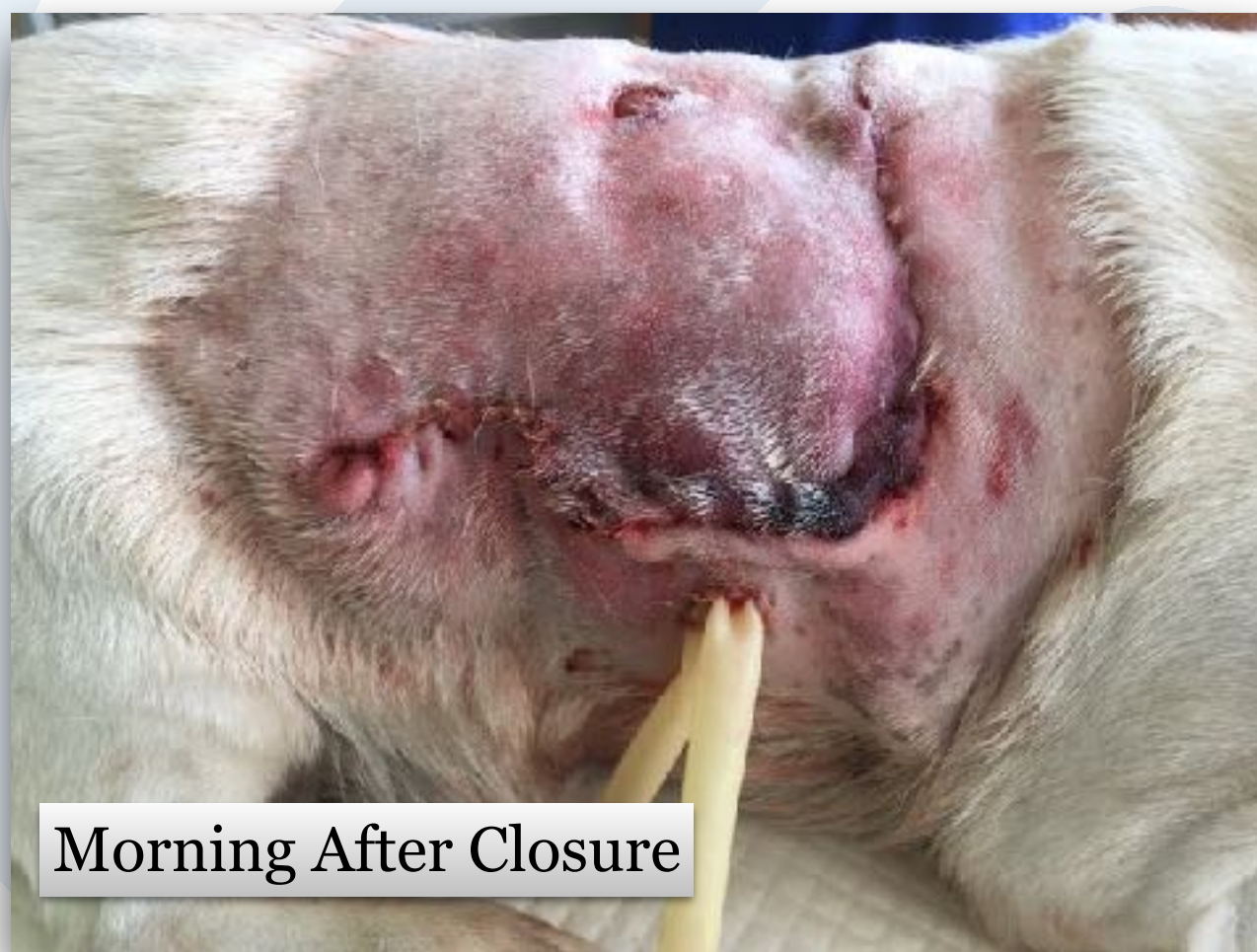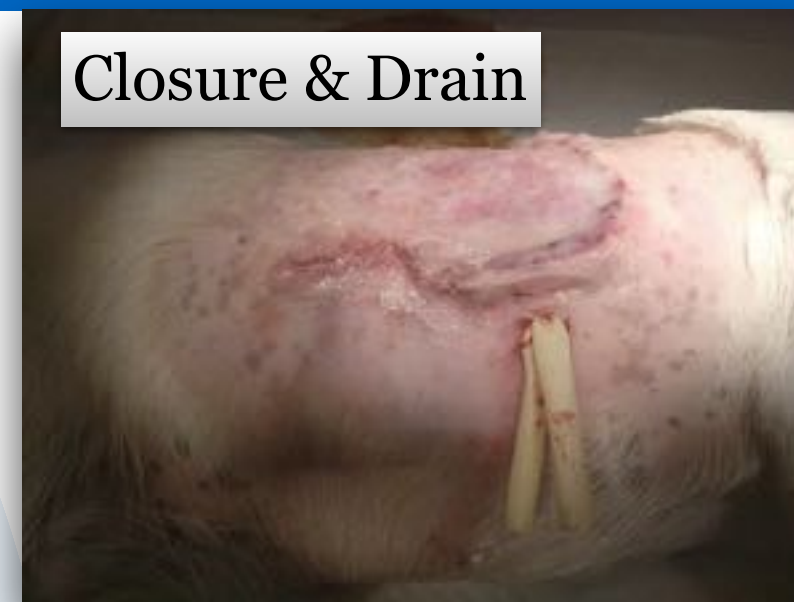# Wound Healing - Ida

Ida, a 15 year old Jack Russell, was attacked by a 60 kg Boerboel.

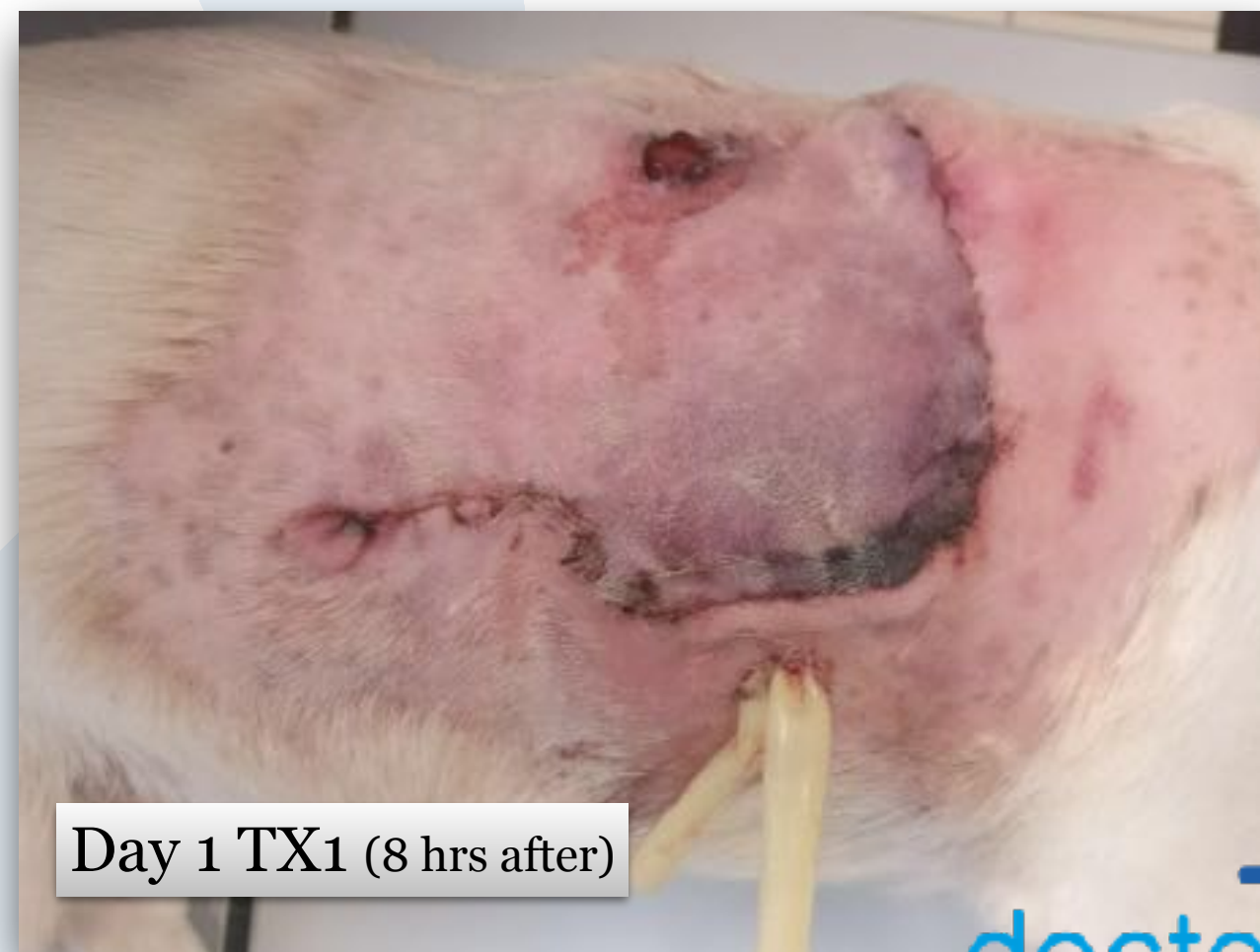
The wound was closed with a drain placement, but we were concerned that part of the skin would become necrotic.

The next morning the wound was swollen and red. I decided to use doctorVet to improve healing with protocols for deep infection, general pain and inflammation.

Closure & Drain



Morning After Closure



Day 1 TX1 (8 hrs after)

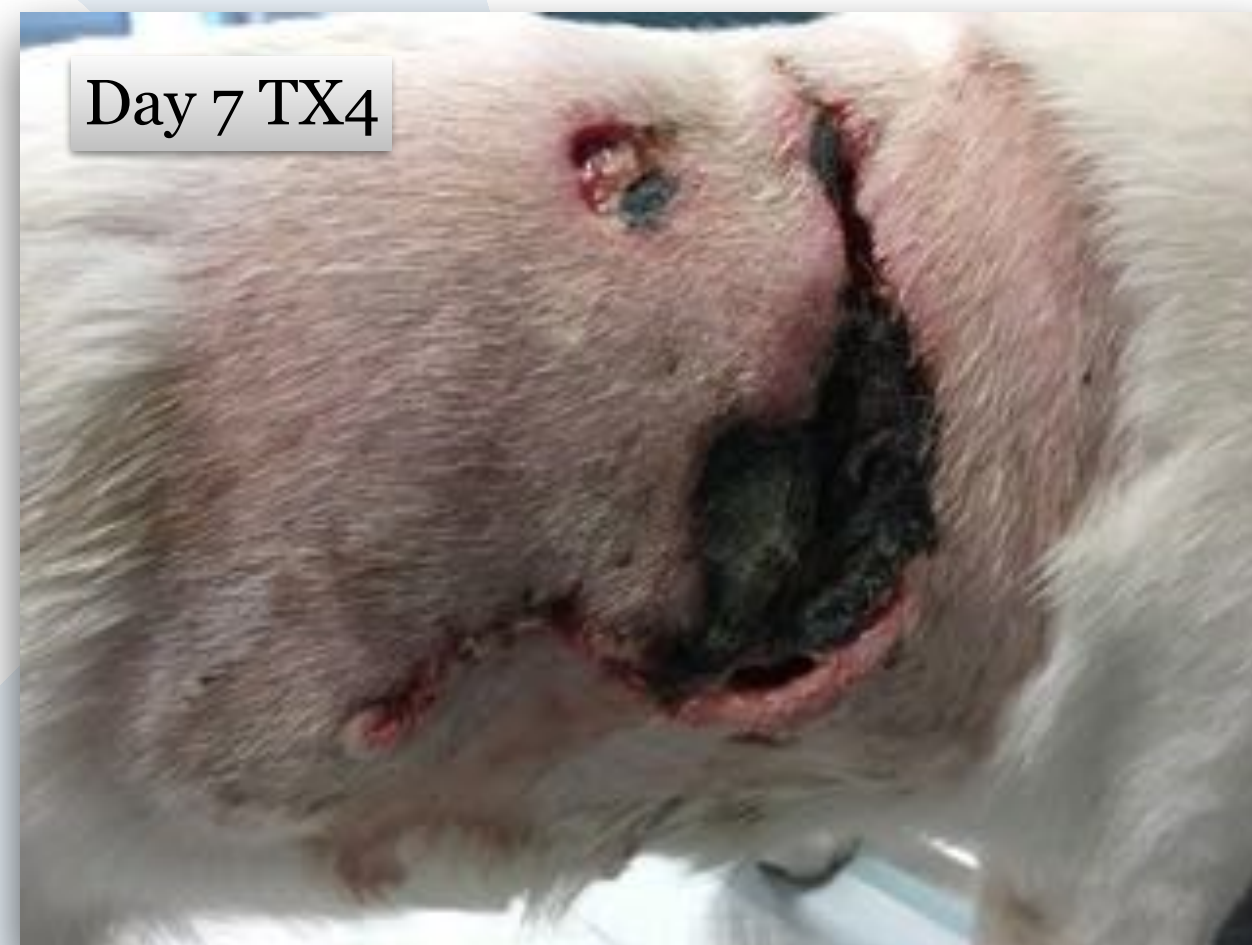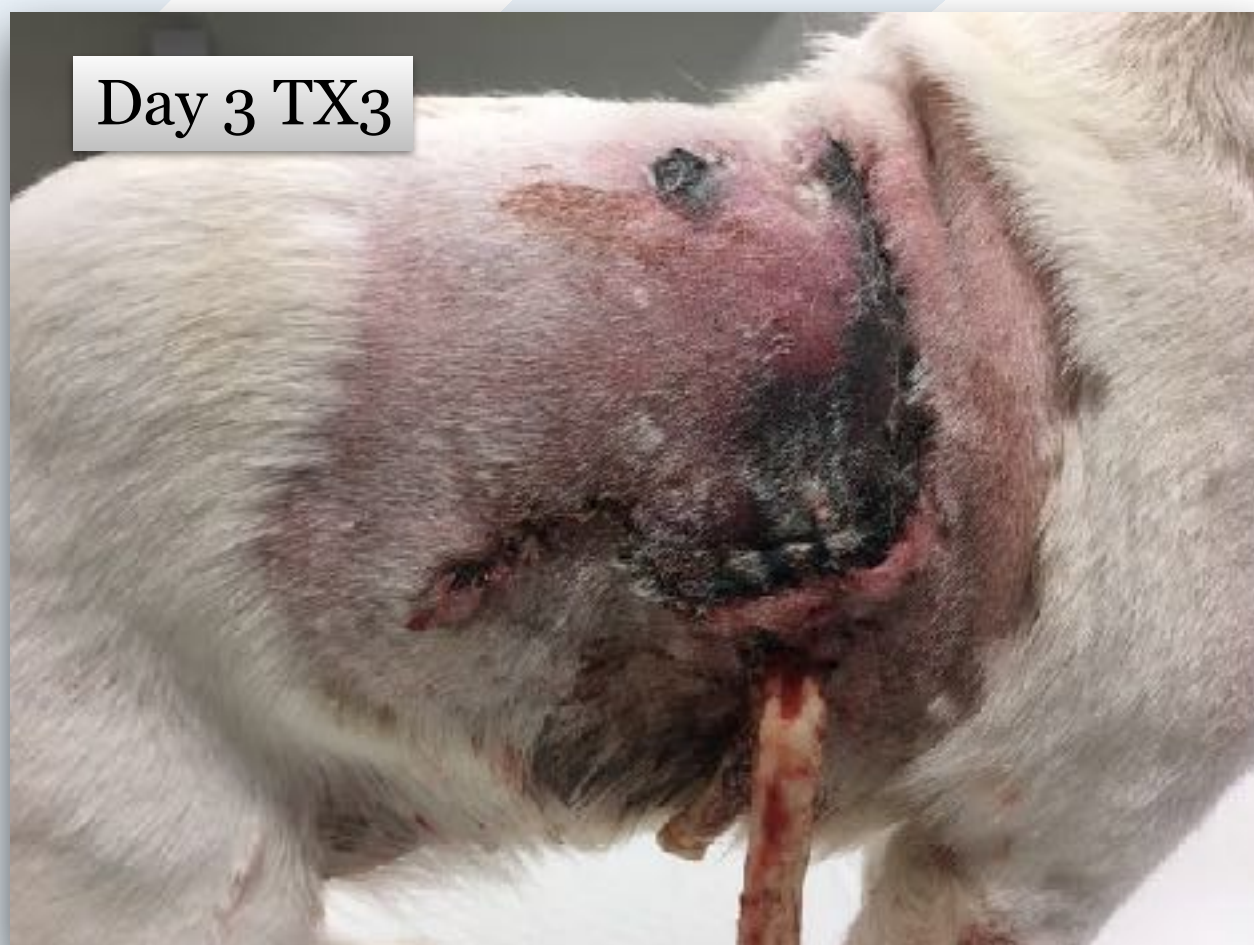*Case Courtesy of Dr. Wendy Haelterman*



# Wound Healing - Ida

Day 3 drain removed and 3rd doctorVet Treatment. Patient discharged with antibiotics and anti inflammatory medication.

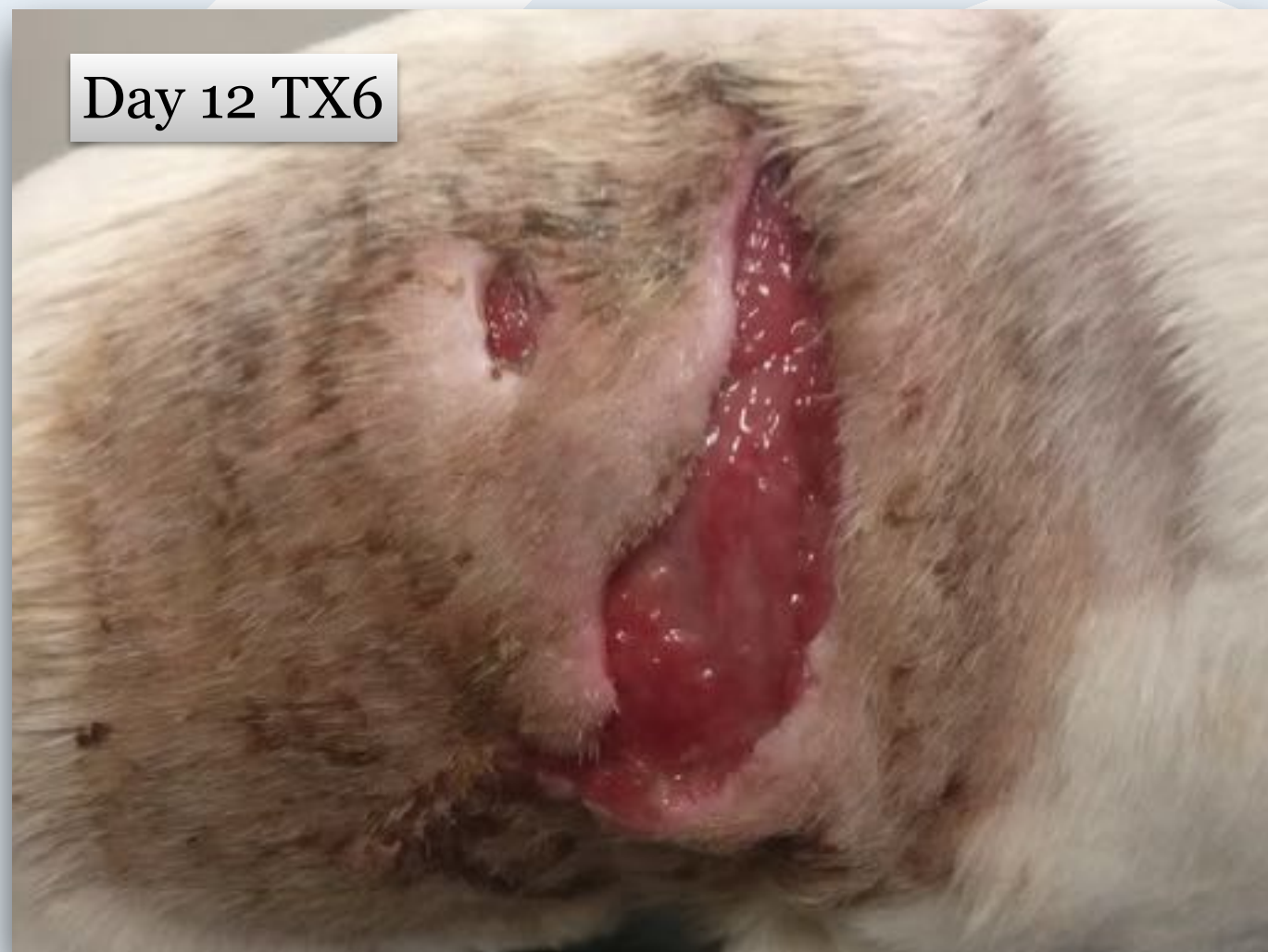Day 7 necrotic tissue removed and 4th doctorVet treatment.



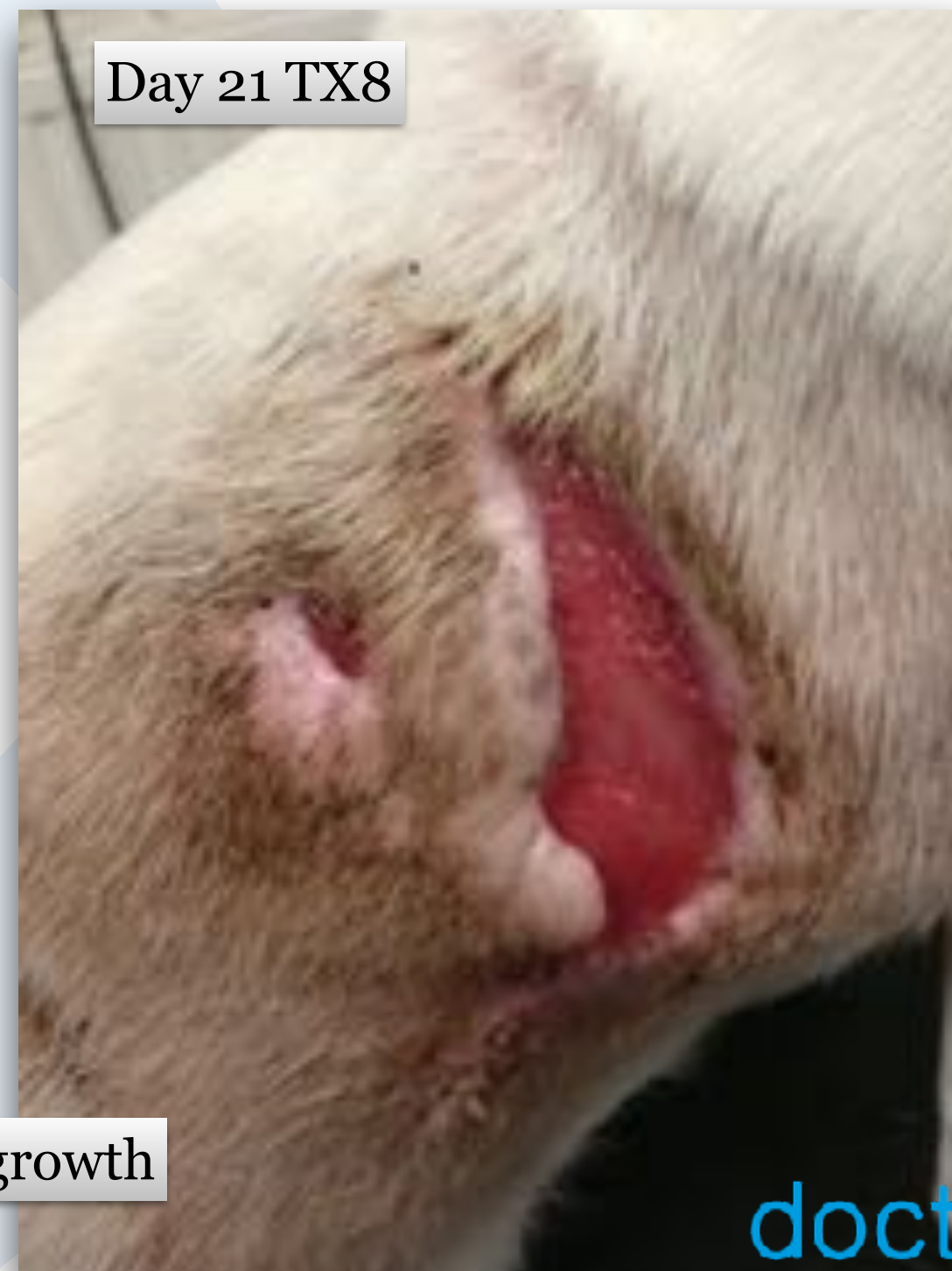

# Wound Healing - Ida

Owners are very happy. They wanted to euthanize Ida because she was in so much pain.



Day 12 TX6



Day 21 TX8

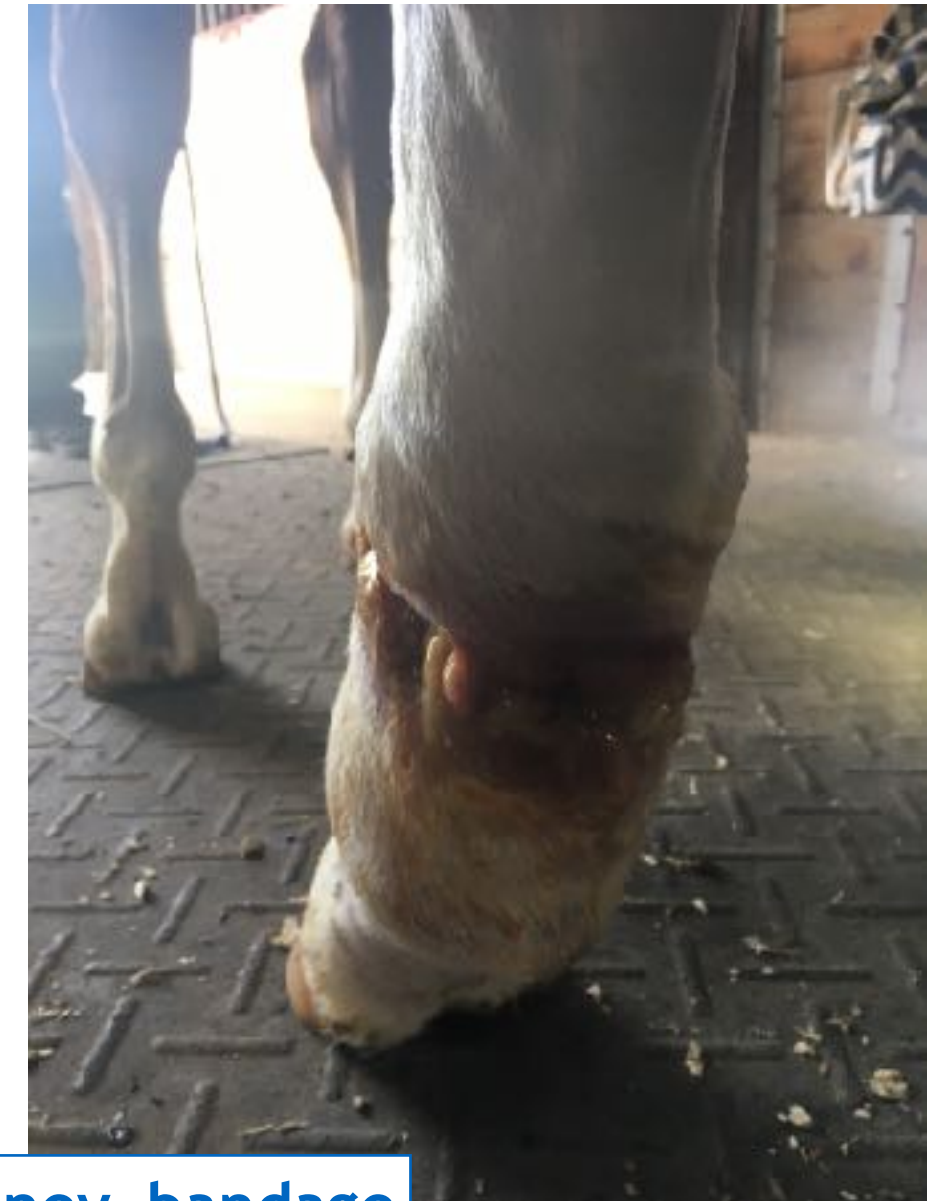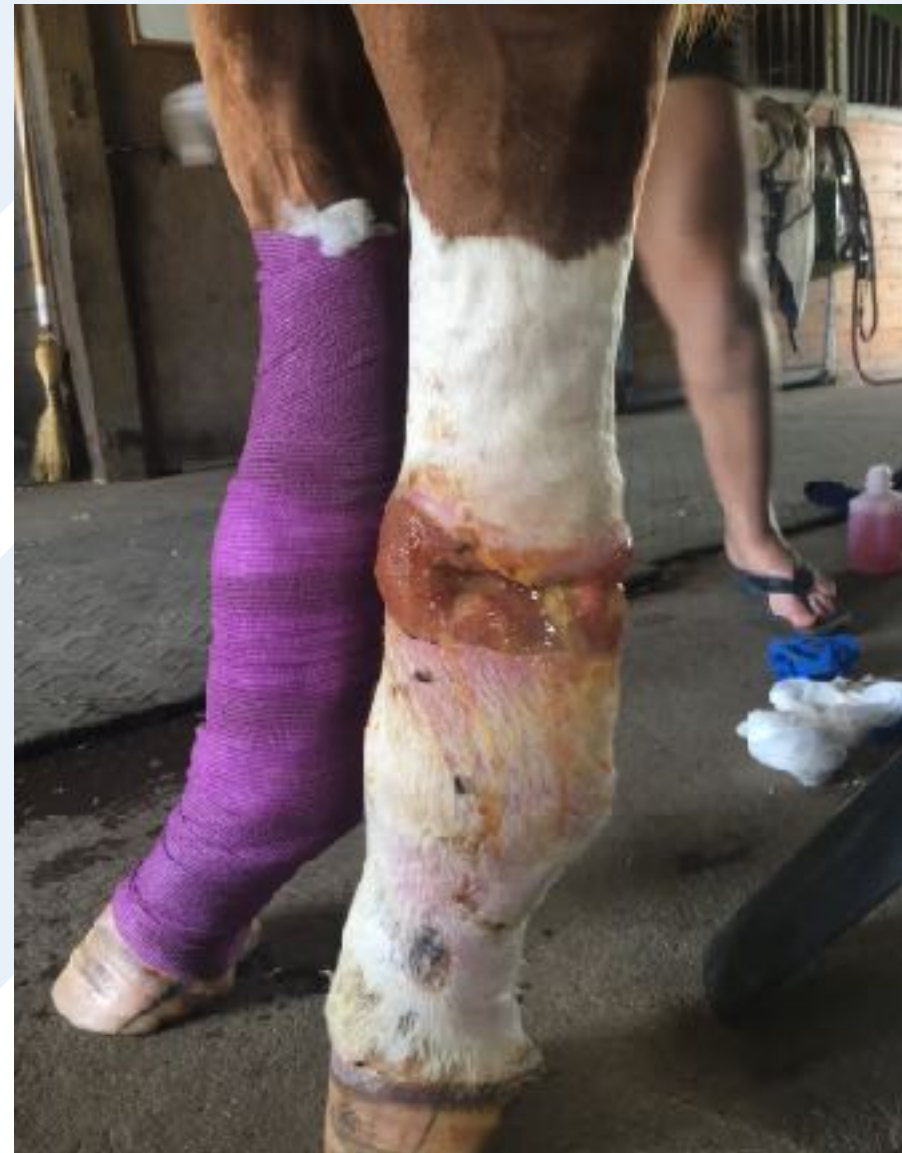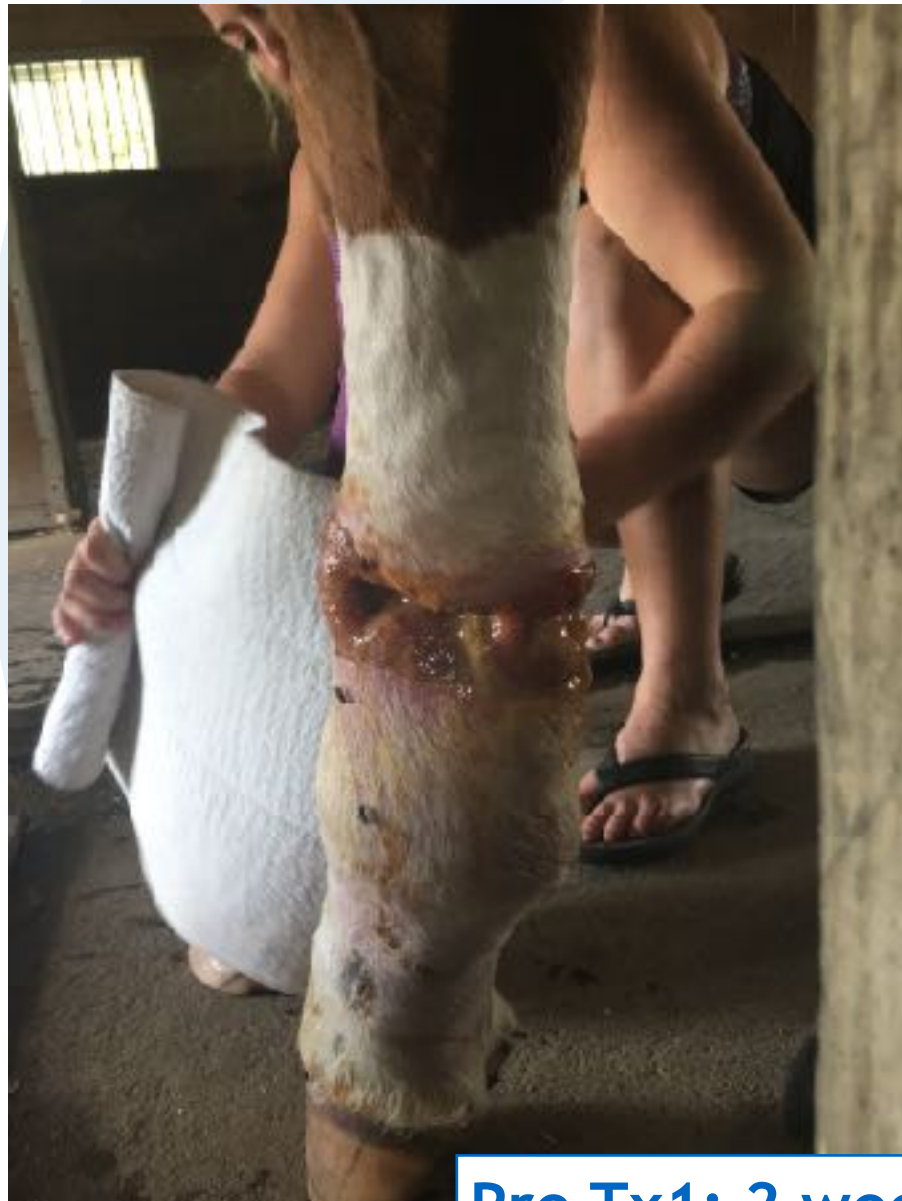Notice Hair Regrowth

*Case Courtesy of Dr. Wendy Haelterman*



# Wound Healing - Equine Lower Limb

14 month old warm blood cross  
Horse caught up in high tensile fencing  
Evaluation of tendons not yet possible on ultrasound because need wound closure to scan  
Not fully weight-bearing



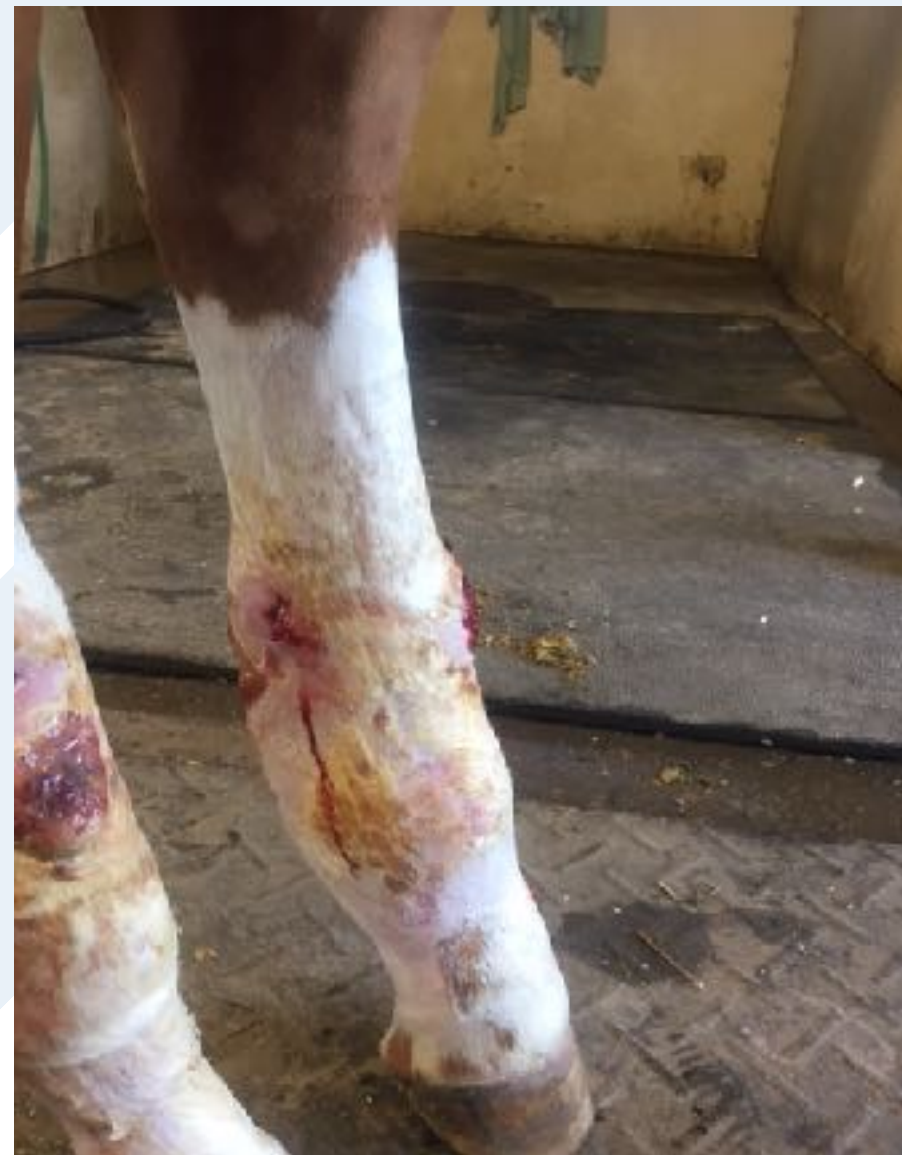
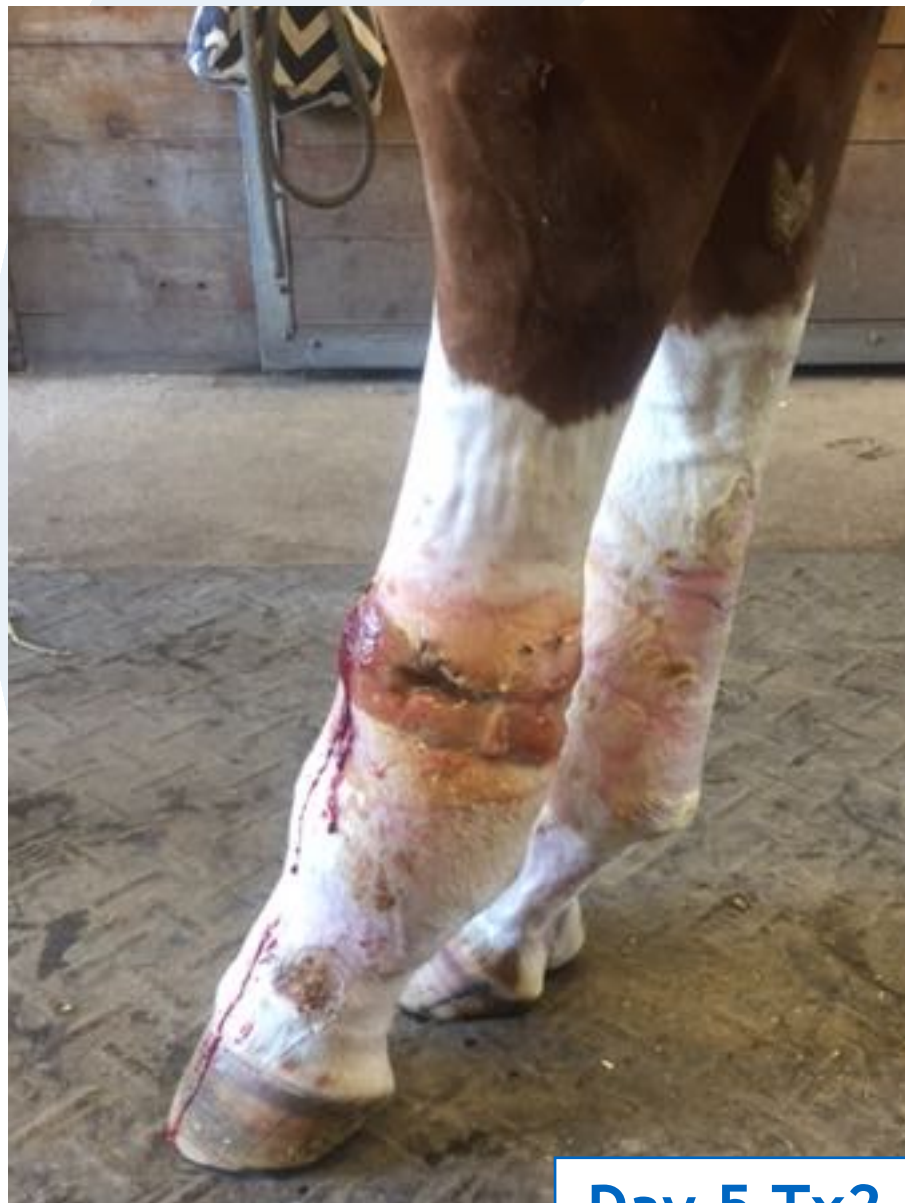Pre Tx1; 2 weeks post-injury; Standard of Care: Manuka honey, bandage



# Wound Healing - Equine Lower Limb

Day 1 Tx 1.1 Wound protocol (100 cm<sup>2</sup>) 10cm above and below wound in grid scan pattern

Also treated on Day 1 Tx 1.2 was Coronet band under inflammation protocol



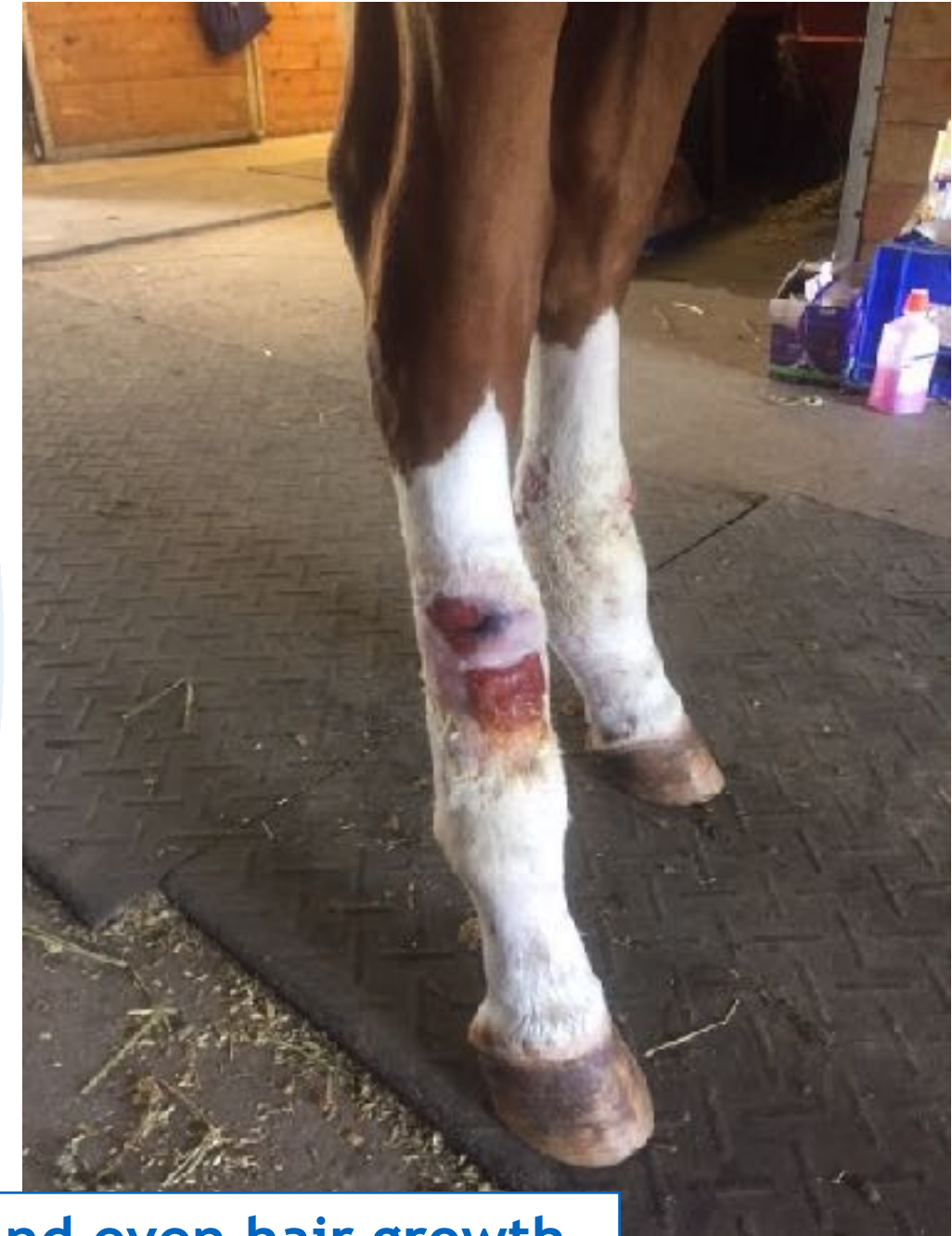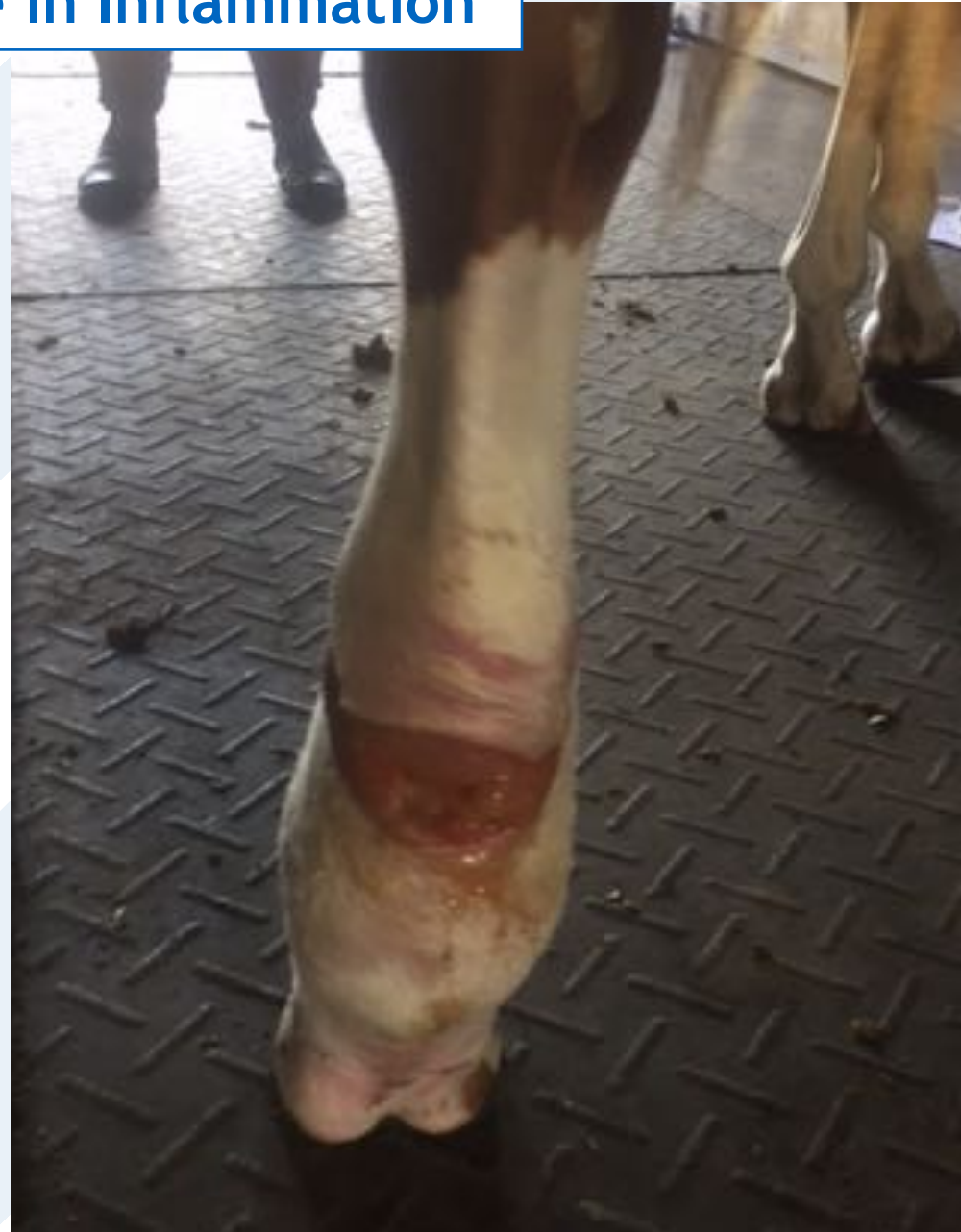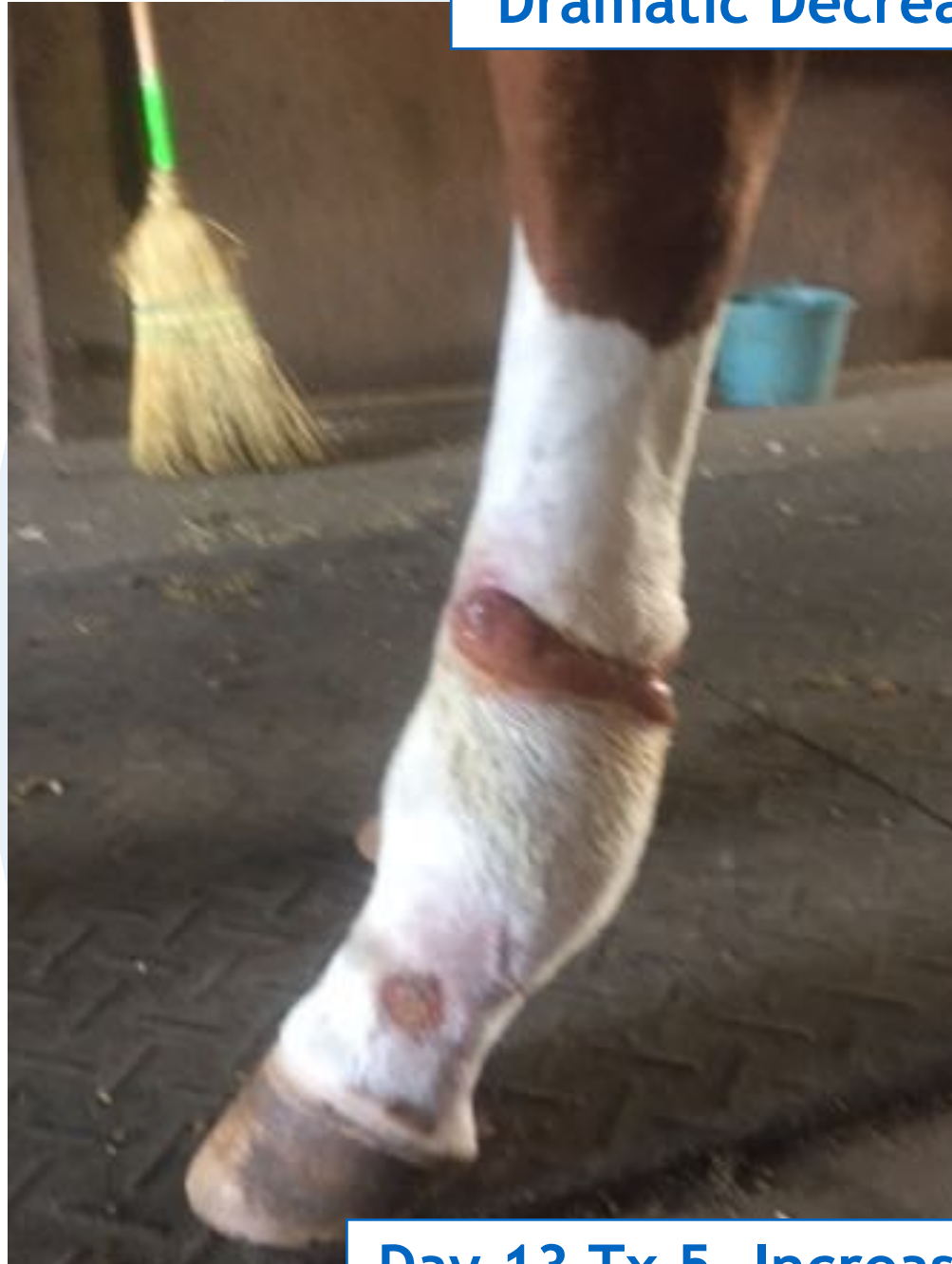Notice Full Weight Bearing

Day 5 Tx2. 40% reduction of size, Dramatic increase in granulation



# Wound Healing - Equine Lower Limb

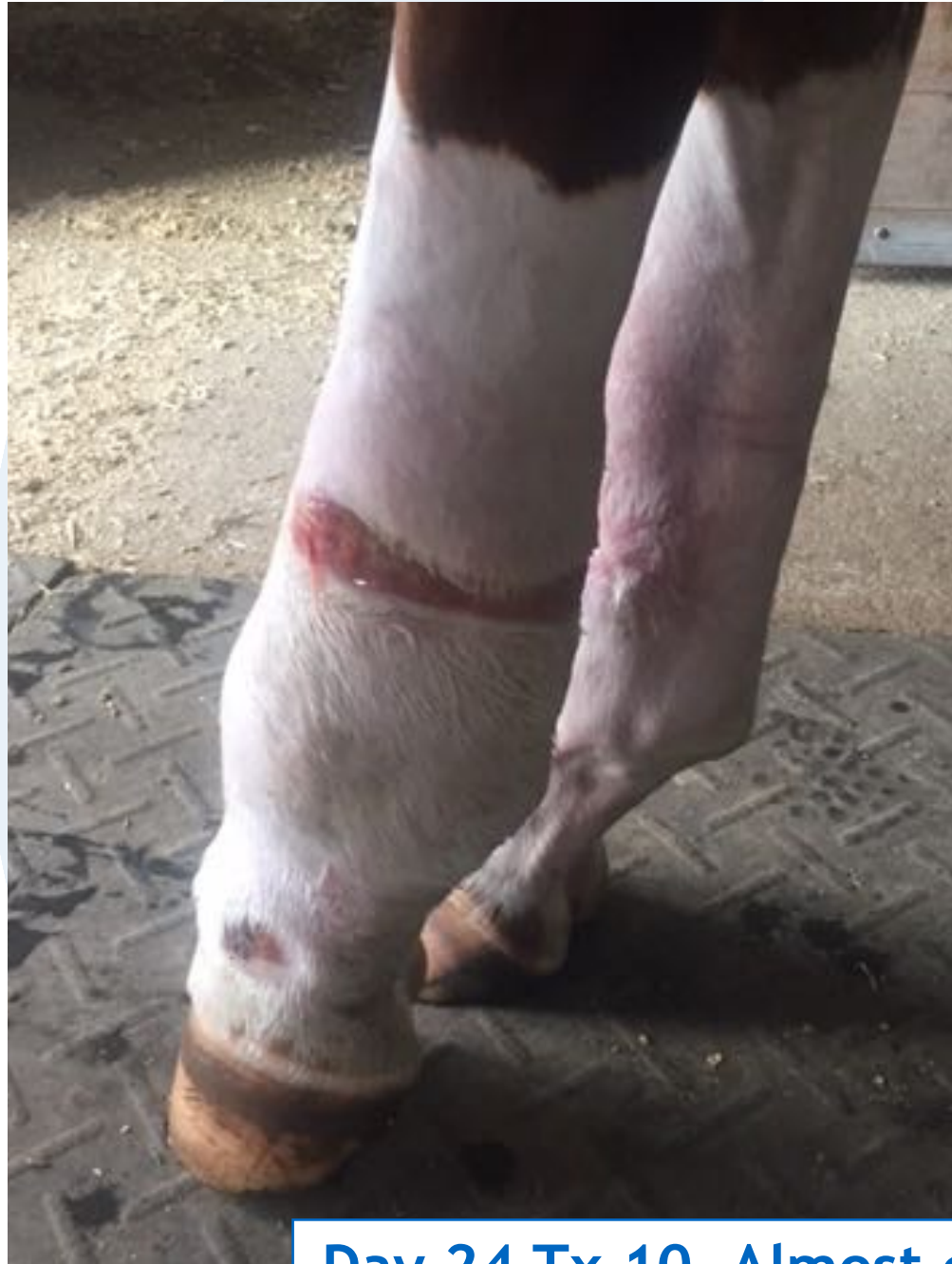**Dramatic Decrease in Inflammation**



**Day 13 Tx 5. Increased epithelialization (wound closure) and even hair growth.**



# Wound Healing - Equine Lower Limb



Day 24 Tx 10. Almost complete wound closure.



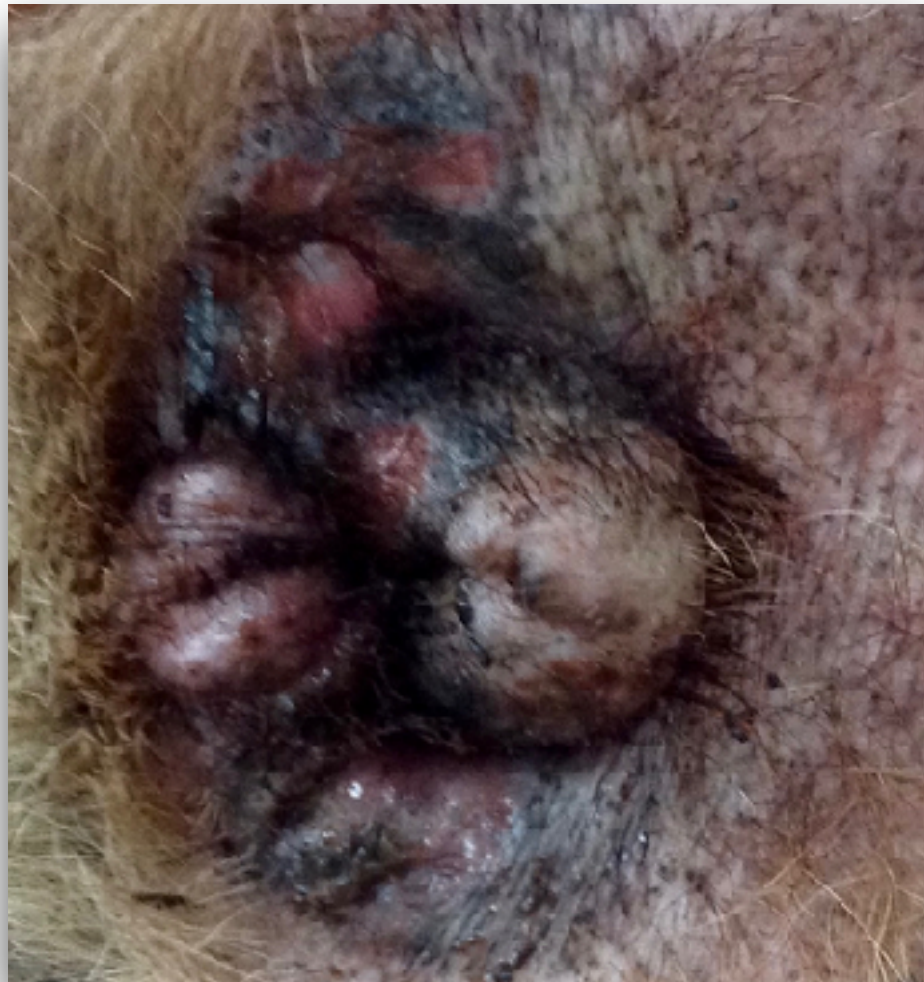Completely reorganized wound bed.



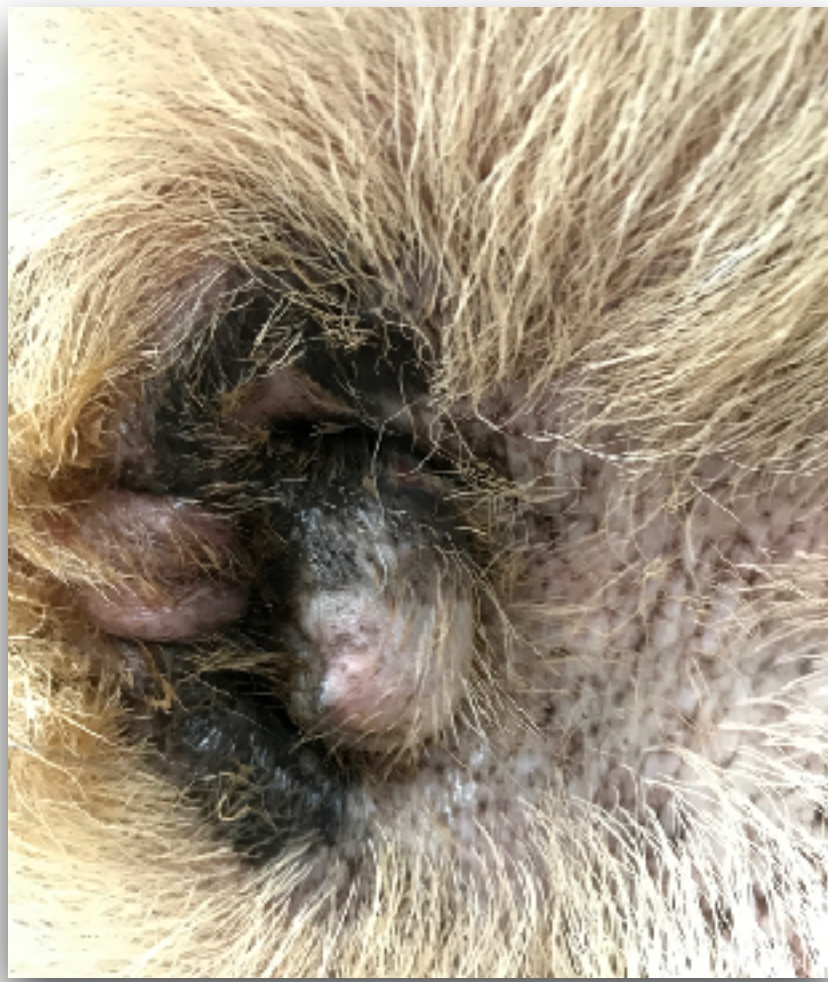# Dakota - 8 YO German Shepherd

“Dakota” is an 8-year-old, female neutered, German shepherd dog suffering from chronic ulcerative dermatitis with secondary superficial pyoderma bacterial infection. We elected to treat it with topical antimicrobial ointment and doctorVet

**Day 0 before Tx**

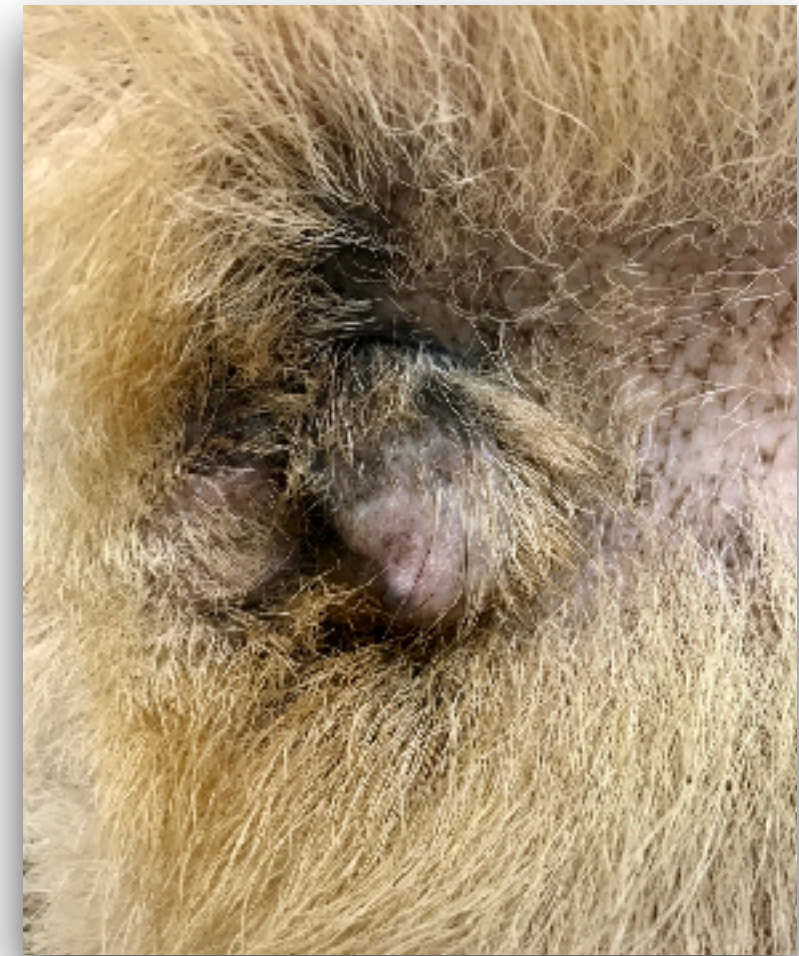

**Day 21 Tx 6**



**No evidence of secondary infections. We start to discontinue the topical ointment**

**Day 42 Tx 10**

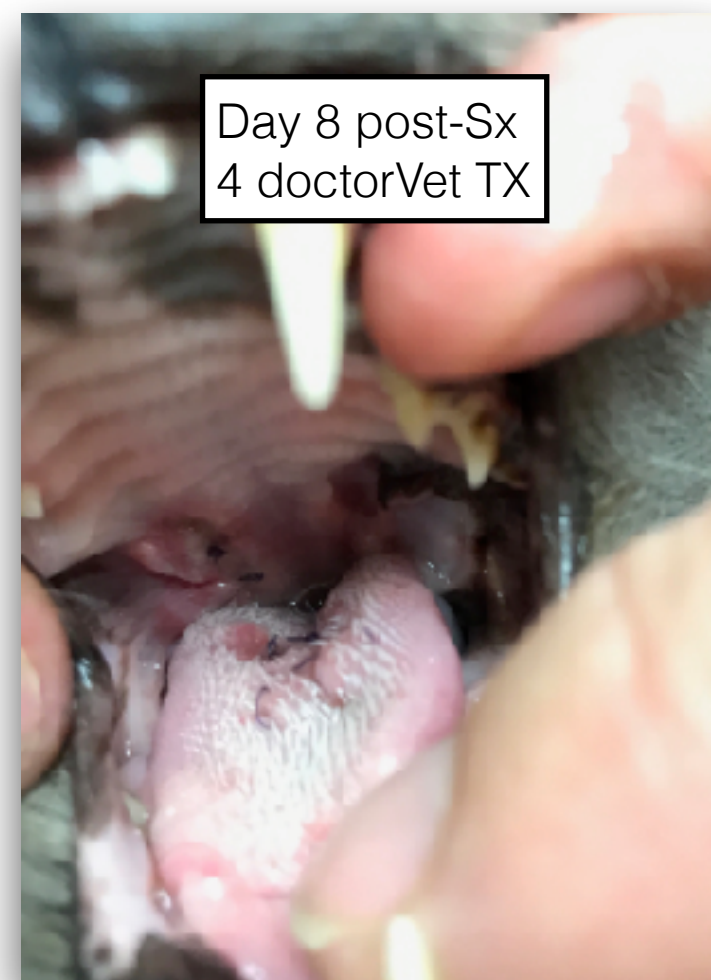
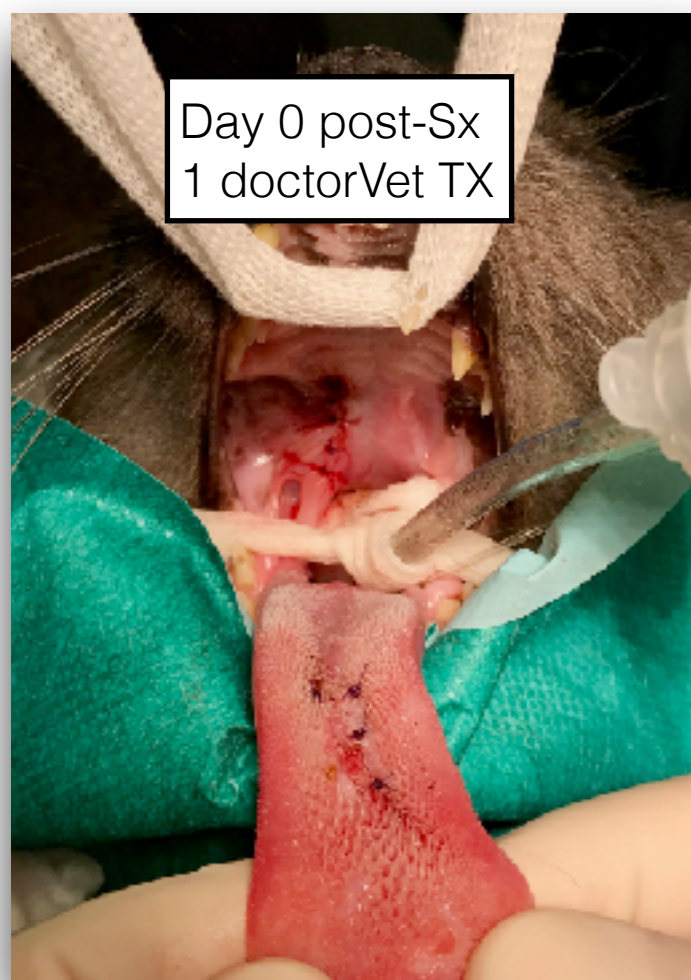
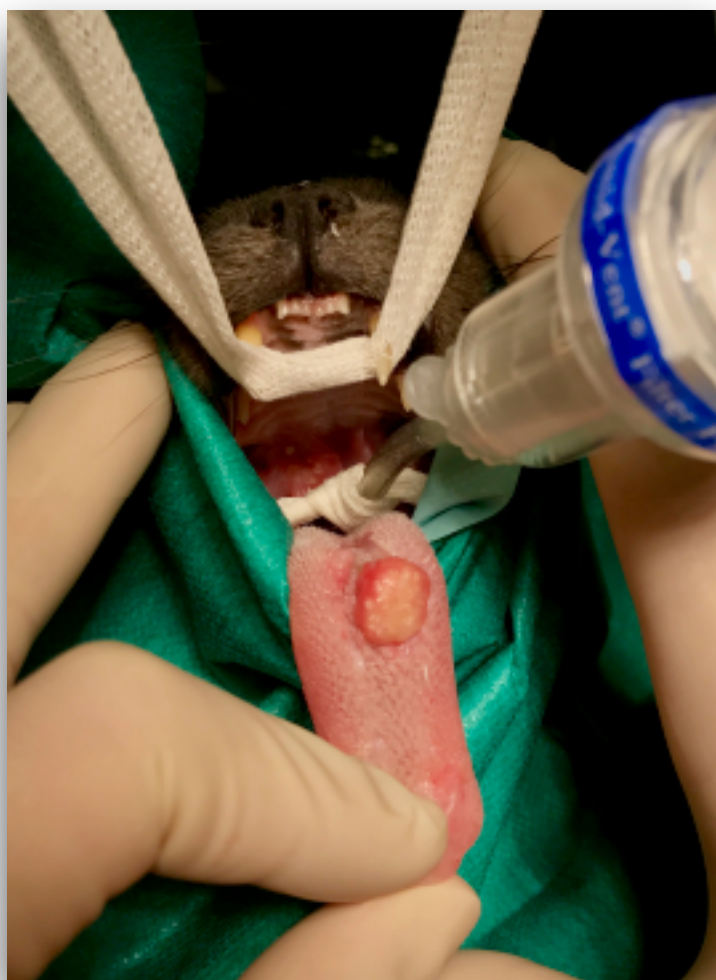**No evidence of ulcerative lesions**



# Eosinophilic Granuloma

“Pepino” is an 11 year-old, male neutered, domestic short-haired cat diagnosed with feline eosinophilic granuloma in the oral cavity. After 6 months of immunosuppressive treatments, still one granuloma was present in the tongue, thus **Aesculight Co2 Laser** and **doctorVet** for wound healing and pain were elected



Neither pain nor ptyalism were observed by owner, cat ate and behaved normally. Surgery wounds were already healed

*Case Courtesy of Dr. Ramon Almela & Dr. Jakub Kaczmarek*